

Colon Cancer Presenting as Abdominal Wall Abscess

Erdinç Kamer , Ahmet Er , Fevzi Cengiz , Serkan Karaisli , Mustafa Peskersoy 

Department of General Surgery, İzmir Katip Çelebi University Atatürk Training and Research Hospital, İzmir, Turkey

ORCID IDs of the authors: E.K. 0000-0002-5084-5867; A.E. 0000-0002-0101-563X; F.C. 0000-0002-1614-5568; S.K. 0000-0001-8876-0191; M.P. 0000-0002-7319-2686.

Cite this article as: Kamer E, Er A, Cengiz F, Karaisli S, Peskersoy M. Colon Cancer Presenting as Abdominal Wall Abscess. *Cyprus J Med Sci* 2018; 3(3): 202-3.

Malignant colon cancer rarely present with anterior abdominal wall abscess. Here we present the case of a patient who underwent radical surgery. A 62-year-old man presented with a locally advanced sigmoid malignant colon tumor with an anterior abdominal wall abscess as preliminary symptom, with no evidence of metastasis to distant organs. We performed sigmoid colectomy with full-thickness resection of the anterior abdominal wall including the abscess. Pathological examination revealed a moderately differentiated adenocarcinoma with no tumor tissue in the surgical margins. Postoperative clinical course was entirely uneventful. The patient remained well for the 2-year follow-up period without recurrence. In this study, we aim to show that radical surgery for locally advanced colon cancer in tertiary care centers procures satisfactory results with regards to disease-free survival and quality of life.

Keywords: Abdominal wall abscess, locally advanced colon cancer, radical surgery

INTRODUCTION

Locally advanced disease, which involve 5%-22% of all colorectal cancers, is a subgroup of colorectal tumors and is characterized by the invasion of adjacent organs without distant metastases (1). Of the estimated 100,000 new colon cancer cases that are diagnosed each year in the United States, locally advanced disease with invasion of adjacent organs or abdominal wall constitutes approximately 10%-20%. These cancers are classified as T4 lesions by the American Joint Committee on Cancer staging schema (2). The formation of an abscess is seen in only 0.3%-4% of all colon cancer cases, and anterior abdominal wall abscesses occur due to malignant tumor invasion and perforation, as reported previously (1, 2). Radical surgery has been rarely performed due to unacceptable high risks and also poor prognosis.

Here we present the diagnosis and treatment of a man treated with radical surgery for locally advanced sigmoid malignant colon tumor complicated by an abscess of anterior abdominal wall.

CASE PRESENTATION

A 62-year-old man was admitted to a district hospital with the symptoms of skin edema and redness in the left anterior abdominal wall. Antibiotic therapy for 7 days did not improve his condition. He developed necrotic skin changes on a fluctuant and indurated area in the left anterior abdominal wall, suggesting an abscess formation, and the patient was referred to our clinic (Figure 1) Contrast-enhanced abdominal computed tomography (CT) scan revealed a gross mass with fluid inside in the lower left quadrant. Separating the mass from the sigmoid colon was challenging (Figure 2). Colonoscopy confirmed a tumor of the sigmoid colon. Carcinoembryonic antigen level was normal. Blood tests revealed white blood cell (WBC) count of 11,200 /mm³ (reference range: 3,500-8,500/mm³) and a C-reactive protein level of 14.58 mg/dL (reference range: <0.3 mg/dL). Drainage of the abdominal wall abscess was performed under local anesthesia. Surgery was planned after symptoms and induration of the abscess had regressed. A sigmoid colectomy with full-thickness resection of the anterior abdominal wall, including the abscess pouch, was performed (Figure 2). Abdominal defect was closed using an AlloDerm regenerative tissue matrix (LifeCell Corporation, Bridgewater, N.J.). The postoperative course was entirely uneventful, and the patient was discharged on the 17th day after surgery. Pathological examination revealed a moderately differentiated adenocarcinoma, ulcerated type with a clear margin, with subserosal invasion and nodal involvement classified as stage IIIC: T4N1M0 according to the Tumor-Node-Metastasis (TNM) classification. Adjuvant therapy was administered, and the patient has remained well for 2 years after surgery without any evidence of tumor recurrence. Written informed consent was obtained from the patient.

This study was presented at the 15th Turkish Colon and Rectal Surgery Congress. 19-23 May, 2015. Antalya, Turkey.

Corresponding Author: Serkan Karaisli
E-mail: skaraisli@hotmail.com

Received: 29.07.2018
Accepted: 14.10.2018

©Copyright 2018 by Cyprus Turkish Medical Association - Available online at cyprusjmedsci.com

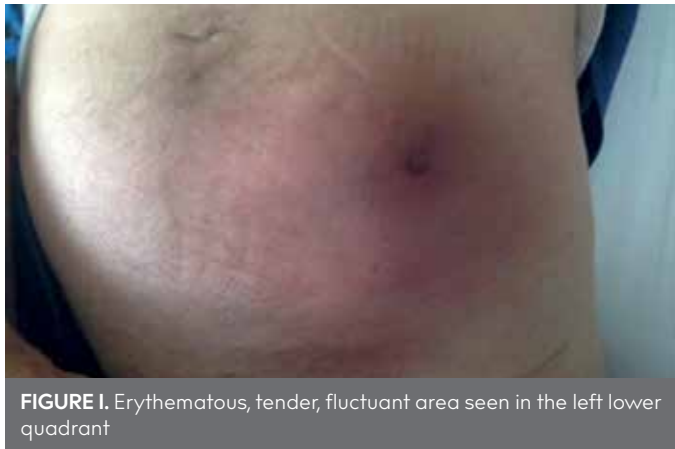

FIGURE 1. Erythematous, tender, fluctuant area seen in the left lower quadrant

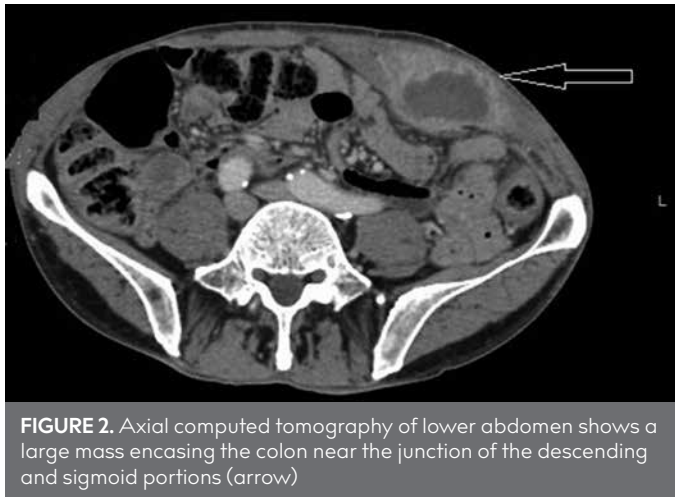


FIGURE 2. Axial computed tomography of lower abdomen shows a large mass encasing the colon near the junction of the descending and sigmoid portions (arrow)

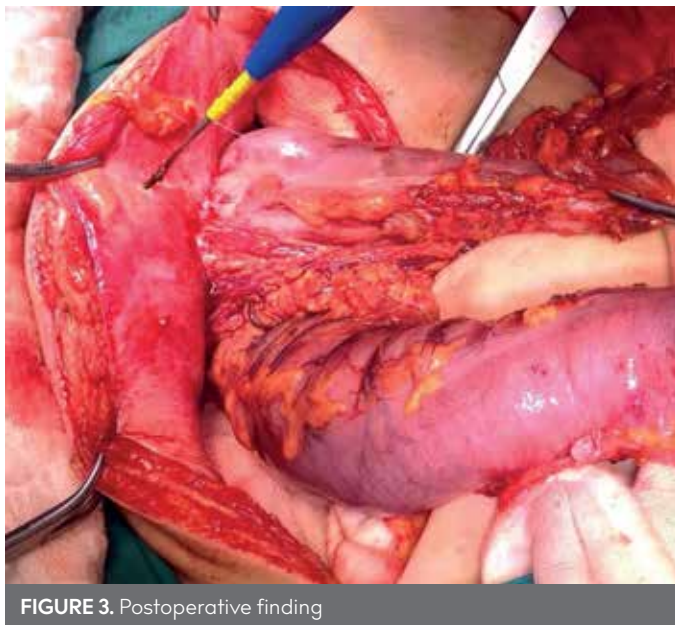


FIGURE 3. Postoperative finding

DISCUSSION

Abdominal wall abscess due to invasion and perforation of the colon tumor is a rare occurrence. Preoperative diagnosis of abdominal wall abscess associated with colon cancer is considered as difficult. However, the source of abscess must be detected by clinicians as quickly as possible. While taking history of the patient and conducting a physical examination, the significant features of abscess, such as fever, pain, skin reddening, or

a palpable mass, may be determined (1). WBC count generally increases in the presence of an abscess. Owing to its peerless imaging sensitivity, CT is an ideal technique to evaluate suspected abscesses, and colorectal cancer appears as wall thickening of colon or a separate mass. Colonoscopy is advantageous to investigate the features and structure of tumor (3).

Complete resection of the malignant colon tumor and the abscess wall is the preferable method. Unless surgery is contraindicated by the patient's general condition, percutaneous aspiration and drainage by indwelling catheter combined with broad-spectrum antibiotics may be applied without further diagnostic work-up (4, 5). However, the drainage procedure may alleviate the toxemia, and, if possible, simultaneous colon resection should be performed to eradicate the main source of sepsis.

Radical surgical approaches are associated with a high rate of morbidity and mortality (1). Radical resection is a challenging procedure for surgeons because, in the presence of local invasion, multivisceral resection is required. Although radical resection is essential in patients for cure, unfortunately, most of patients exhibit bad general conditions. Abdominal wall reconstruction is necessary in terms of resection of the abdominal wall muscles and fascia. Primary repair of abdominal wall often fails owing to high tension, and the failure rate of the primary repair may reach up to 50% (1, 2). On the other hand, large abdominal wall defects related to full-thickness resection of the invasive malignant tumors are not recommended to be closed by primary sutures.

Therefore, perforated colon cancer with abscess formation may be first treated with local drainage of the abscess and the use of appropriate antibiotics and then the resection of the colon and anterior abdominal wall with adequate drainage.

Informed Consent: Written informed consent was obtained from the patient who participated in this study.

Peer-review: Externally peer-reviewed.

Author contributions: Concept - E.K., S.K.; Design - A.E., F.C.; Supervision - E.K., M.P.; Resource - S.K., A.E.; Materials - F.C., S.K.; Data Collection and/or Processing - E.K., A.E.; Analysis and/or Interpretation - F.C., M.P.; Literature Search - S.K., F.C.; Writing - E.K., S.K.; Critical Reviews - E.K., M.P.

Acknowledgements: The authors would like to thank the staff at the General Surgery Department for their cooperation.

Conflict of Interest: The authors have no conflicts of interest to declare.

Financial Disclosure: The authors declared that this study has received no financial support.

REFERENCES

- Okita A, Kubo Y, Tanada M, Kurita A, Takashima S. Unusual Abscesses Associated with Colon Cancer: Report of Three Cases. *Acta Med Okayama* 2007; 61: 107-13.
- Landmann RG, Weiser MR. Surgical Management of Locally Advanced and Locally Recurrent Colon Cancer. *Clin Colon Rectal Surg* 2005; 18: 182-9. [[CrossRef](#)]
- Rega D, Cardone E, Catalano O, Montesarchio L, Pace U, Scala D, et al. Locally advanced colon cancer with abdominal wall abscess: A challenging case treated by an innovative approach. *Journal of Cancer Therapy* 2012; 3: 966-9. [[CrossRef](#)]
- John K, Gur U, Cade D. Carcinoma of Sigmoid Colon Presenting as Abdominal Wall Abscess. *Indian J Gastroenterol* 2002; 21: 117-8.
- Hung HY, Yeh CY, Changchien CR, Chen JS, Fan CW, Tang R, et al. Surgical Resection of Locally Advanced Primary Transverse Colon Cancer-Not a Worse Outcome in Stage II Tumor. *Int J Colorectal Dis* 2011; 26: 859-65. [[CrossRef](#)]