

## Esophagus Perforation Caused by a Foreign Body

Turan Acar<sup>1</sup>, Nihan Acar<sup>1</sup>, Özgür Yıldırım<sup>1</sup>, Firdevs Topal<sup>2</sup>, Mehmet Hacıyanlı<sup>1</sup>

<sup>1</sup>Department of General Surgery, İzmir Katip Çelebi University Atatürk Training and Research Hospital, İzmir, Turkey

<sup>2</sup>Department of Gastroenterology, İzmir Katip Çelebi University Atatürk Training and Research Hospital, İzmir, Turkey

Esophagus perforation caused by a foreign body is a rare condition. Management of these cases is quite challenging. Although diagnostic techniques, antibiotics, and surgical procedures have highly developed in recent years, morbidity and mortality rates are still high. In this article, we aimed to present our treatment management for a patient with esophageal perforation caused by a chicken bone. A 61-year-old male patient was admitted to the emergency department with sudden dyspnea and chest pain, which occurred while having dinner. Laboratory tests were normal, except for the presence of leukocytosis. Chest X-rays showed the elevation of the left hemidiaphragm and mediastinal air. As the endotracheal examination was normal, esophageal perforation was considered in the patient. Emergency endoscopy was performed in the patient. A chicken bone was found in the middle part of the esophagus lumen. The chicken bone was removed using a basket, and the perforation area was closed with endoscopic clips. Endoscopic interventions have an important role in the diagnosis and treatment of esophageal perforations.

**Keywords:** Endoscopy, esophagus, perforation, foreign body, clips

### INTRODUCTION

Esophageal perforation is a vital and urgent condition with high morbidity and mortality rates (1). Approximately 70% of the cases present esophageal perforation following a diagnostic or therapeutic intervention. Esophageal perforation caused by a foreign body is very rare (8%). Management of these cases is quite challenging. Although diagnostic techniques, antibiotics, and surgical procedures have highly developed in recent years, the morbidity and mortality rates are still high. In this article, we aimed to present our treatment management for a patient with esophageal perforation caused by a chicken bone.

### CASE PRESENTATION

A 61-year-old male patient was admitted to the emergency department with sudden dyspnea and chest pain, which occurred while having dinner. He had a medical history of hypertension and coronary artery disease. He was taking an antihypertensive drug and acetylsalicylic acid (aspirin 100 mg) for these conditions. Abdominal examination was normal, and decreased breath sounds were noted during auscultation. Laboratory tests were normal, except for the presence of leukocytosis (22.14 K/uL). Chest X-rays showed an elevation of the left hemidiaphragm and mediastinal air. Upon these findings, a thoracic computed tomography (CT) scan was performed and showed diffuse mediastinal air (Figure 1). Fluoroscopic examination with a water-soluble contrast could not be sufficient for a clear diagnosis. As the endotracheal examination was normal, esophageal perforation was considered. Emergency endoscopy was performed on patients. A chicken bone was found in the lumen of the middle part of the esophagus. The chicken bone was removed using a basket, and the perforation area was closed with three endoscopic clips (Boston Resolution Clip, Boston Scientific; Natick, Massachusetts, USA). After the procedure, because of a sudden decrease in oxygen saturation, the patient was intubated and had been hospitalized in the intensive care unit. A broad-spectrum antibiotic was initiated for mediastinitis (Tazocin 4.5 g intravenous flacon (Piperacillin Sodium+Tazobactam Sodium), Pfizer; Berkshire, United Kingdom). The patient stayed for 12 days in the intensive care unit and 4 days in the general surgery ward. Control thoracic CT showed that the endoscopic clips were in the right place and the mediastinal air was resorbed (Figure 2). The patient was discharged from hospital after recovery. He has been followed up for 24 months and does not have any complaint.

Informed consent was obtained from both patients. Consents were also obtained to conduct scientific studies.

### DISCUSSION

Esophageal perforations are usually iatrogenic, spontaneous, traumatic, or secondary to neoplasms. Most of the cases in the literature have been reported as secondary to endoscopic procedures. In the literature, there are very few articles about esophageal perforation caused by a foreign body.

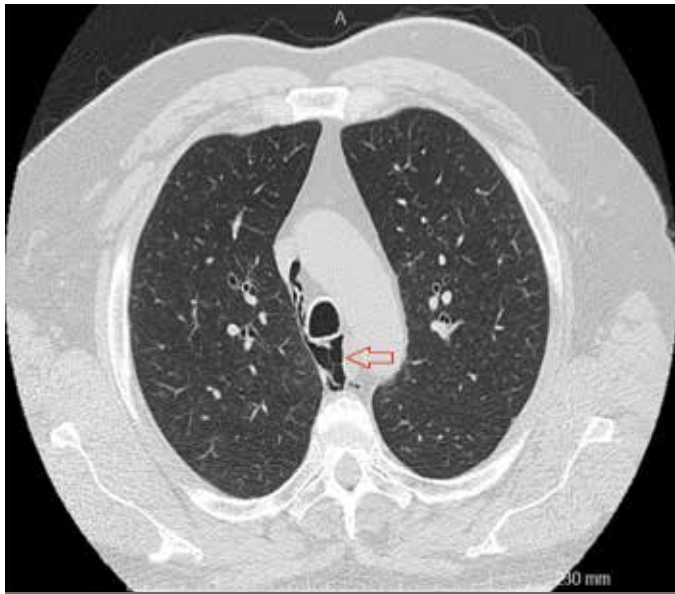


FIGURE 1. Diffuse mediastinal air (marked with circle)

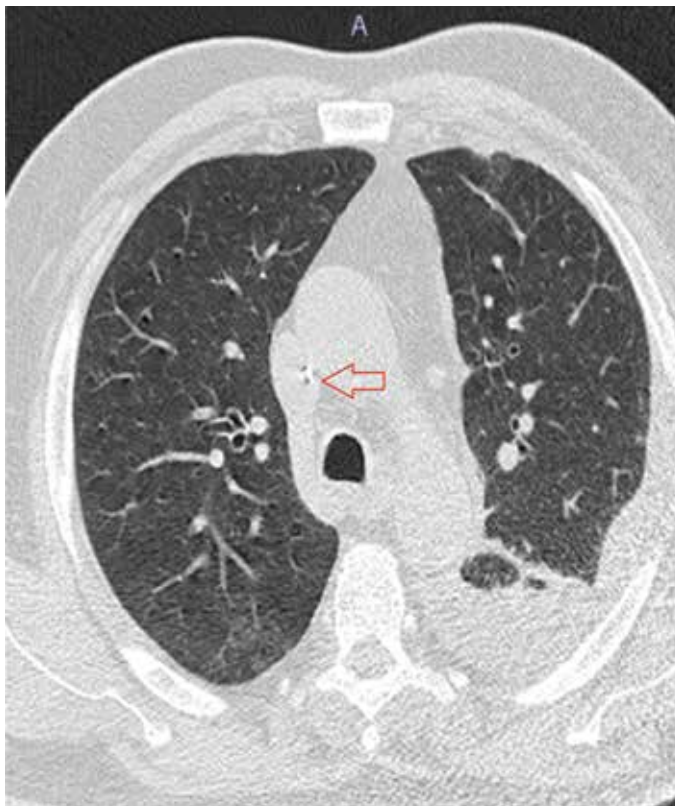

FIGURE 2. The mediastinal air was resorbed (marked with circle)

Because of the proximity to vital organs and severe bleeding tendency, the mortality rate is approximately 65% when the esophagus is perforated. A significant experience is required because of the difficulties in diagnosis and insidious progress of symptoms. In case of a possible delay, the mortality rate increases further (2).

The occurrence of the earliest symptoms varies depending on the time of perforation, size, location, and contamination. Chest pain is the most common symptom. Less often, patients may

present with dysphagia and dyspnea. Our patient also had a diffuse chest pain.

Various diagnostic tests may be used for confirmation of the diagnosis. First, chest X-rays and then CT scans show mediastinal air (3). Additionally, endoscopic or fluoroscopic examinations with water-soluble contrast agents are frequently used. There is a risk of injury and contamination in endoscopy. In addition, because of the possibility of missing the small perforation areas, it is not highly recommended (4). However, in patients with delayed and diffuse mediastinitis, high morbidity and mortality rates of open surgery should be considered. Diagnosis and also treatment with endoscopy can be easily performed in these patients.

Our patient had a diffuse mediastinitis at the time of admission to the hospital. When endoscopy was performed after CT scans, the bone, which stuck in and perforated the esophagus, was extracted, and the perforation area was successfully repaired with clips.

There is no consensus on the surgical treatment options in the literature. The treatment approach may vary depending on presence of sepsis and the location and size of the lesion (5, 6). The key to the optimum management is early diagnosis and the level of injury. The most favorable outcome is obtained following the primary closure of the perforation within 24 h, resulting in 80%–90% survival. These rates are more about the injuries at the cardioesophageal level, which have been assessed by an abdominal approach. A probable thoracotomy increases both morbidity and mortality rates. Therefore, it is necessary to choose the procedures that are as minimally invasive as possible.

In some selected cases, if there is no perforation to the pleural cavity, non-operative (conservative) treatment can be preferred. Conservative treatment selection requires good decision-making skills and a careful radiological examination.

Esophageal foreign bodies are safely removed by endoscopic procedures. If perforation is detected, repair with clips or placing an eluting stent may be attempted simultaneously. We believe that with a proper management, the morbidity and mortality rates will be significantly reduced.

**Informed Consent:** Written informed consent was obtained from patient who participated in this study.

**Peer-review:** Externally peer-reviewed.

**Author contributions:** Concept - T.A., N.A.; Design - T.A., N.A., M.H.; Supervision - M.H.; Resource - F.T., M.H.; Materials - T.A., Ö.Y., F.T.; Data Collection &/or Processing - T.A., Ö.Y.; Analysis &/or Interpretation - T.A., F.T.; Literature Search - T.A., M.H.; Writing - T.A., N.A.; Critical Reviews - M.H., F.T.

**Acknowledgements:** The authors thank all the General Surgery and Gastroenterology staff for their cooperation.

**Conflict of Interest:** No conflict of interest was declared by the authors.

**Financial Disclosure:** The authors declared that this study has received no financial support.

## REFERENCES

1. Udelnow A, Huber-Lang M, Juchems M, Träger K, Henne-Bruns D, Würl P. How to treat esophageal perforations when determinants

- and predictors of mortality are considered. *World J Surg* 2009; 33: 787-96. [\[CrossRef\]](#)
2. Vidarsdottir H, Blondal S, Alfredsson H, Geirsson A, Gudbjartsson T. Oesophageal perforations in Iceland: a whole population study on incidence, aetiology and surgical outcome. *Thorac Cardiovasc Surg* 2010; 58: 476-80. [\[CrossRef\]](#)
  3. Eroglu A, Can Kürkçüoğlu I, Karaoganoğlu N, Tekinbaş C, Yılmaz O, Başoğlu M. Esophageal perforation: the importance of early diagnosis and primary repair. *Dis Esophagus* 2004; 17: 91-4. [\[CrossRef\]](#)
  4. Zwischenberger JB, Savage C, Bidani A. Surgical aspects of esophageal disease: perforation and caustic injury. *Am J Respir Crit Care Med* 2002; 165: 1037-40. [\[CrossRef\]](#)
  5. Huber-Lang M, Henne-Bruns D, Schmitz B, Wuerl P. Esophageal perforation: principles of diagnosis and surgical management. *Surg Today* 2006; 36: 332-40. [\[CrossRef\]](#)
  6. Okten I, Cangir AK, Ozdemir N, Kavukçu S, Akay H, Yavuzer S. Management of esophageal perforation. *Surg Today* 2001; 31: 36-9. [\[CrossRef\]](#)