

Cutaneous Mucinosis Case with Characteristic Lion Face Appearance

Selami Aykut Temiz¹ , Recep Dursun¹ , Arzu Ataseven¹ , İlkey Özer¹ , Siddika Findik² 

¹Department of Dermatology, Necmettin Erbakan University Meram School of Medicine, Konya, Turkey

²Department of Pathology, Necmettin Erbakan University Meram School of Medicine, Konya, Turkey

ORCID IDs of the Author: S.A.T: 0000- 0003-4878-0045; R.D.: 0000-0002-1279-574X; A.A.: 0000-0001-5372-0712; İ.Ö.: 0000-0001-6170-0930; S.F.: 0000-0002-3364-7498

Cite this article as: Temiz SA, Dursun R, Ataseven A, Özer İ, Findik S. Cutaneous Mucinosis Case with Characteristic Lion Face Appearance. *Cyprus J Med Sci* 2018; 3: 117-9.

ABSTRACT

Cutaneous mucinosis includes a heterogeneous group of skin diseases characterized by the deposition of mucin in the interval of the dermis. Mucin is a protein ordinarily found as part of the dermal connective tissues. Mucin is a mucopolysaccharide produced by mast cells and fibroblasts and includes hyaluronic acid and sulfated glycosaminoglycans. Because hyaluronic acid holds water, in disease states where mucin production is increased, the dermal connective tissue swells, which is defined as myxedematous. Systemic mucin deposition may include systemic involvement; monoclonal gammopathy or paraproteinemia have been detected in the large majority (83.2%) of scleromyxedema cases.

A 50-year-old female presented with pruritic, flesh-colored papules spread throughout the body. She also exhibited a characteristic lion face appearance. These lesions had first appeared 18 months before in the neck. The protein electrophoresis and bone marrow biopsy of the patient were normal. Histopathological examination revealed widespread mucin accumulation with alcian blue and colloidal iron stains in the papillary and reticular dermis. Granulomas were not observed with CD68 staining, and no accumulation was observed with amyloid staining. The final diagnosis was cutaneous mucinosis.

In this paper we present the case of a patient with generalized primary cutaneous mucinosis without any systemic disease.

Keywords: Cutaneous mucinosis, lion face, scleromyxedema, hydroxychloroquine

INTRODUCTION

Mucin is a protein ordinarily found as part of the dermal connective tissues (1). Mucin is a mucopolysaccharide produced by mast cells and fibroblasts and includes hyaluronic acid and sulfated glycosaminoglycans (1). Because hyaluronic acid holds water, in disease states where mucin production is increased, the dermal connective tissue swells, which is defined as myxedematous (1).

Cutaneous mucinosis encompasses a heterogeneous group of skin diseases characterized by the deposition of mucin in the interval of the dermis (2). These disorders can be defined as primary mucinosis, with mucin deposition as the principal histologic presentation resulting in clinically prominent lesions, or secondary mucinosis, with mucin deposition as an extra histologic detection within the context of an uncommitted skin disease or lesions with deposits of mucin in the stroma (2).

In this document, we present the case of a patient with generalized primary cutaneous mucinosis without any systemic disease.

CASE PRESENTATION

A 50-year-old female presented with pruritic, flesh-colored papules spread throughout the body. These papular lesions had first appeared 18 months before in the neck. Migraine was noted in the patient's medical history. There was no characteristic in her family medical history. Now retired, she previously worked in a paint factory. Dermatologic examination revealed papular lesions on the entire body, including the face. These lesions were particularly prevalent on the arms

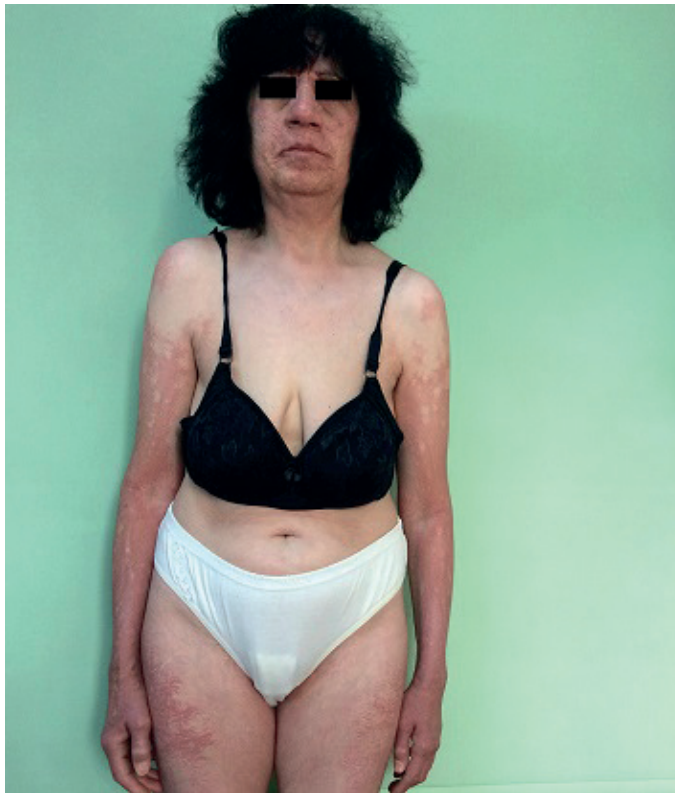

FIGURE 1. Papular lesions on the entire body, including the face; these lesions were particularly prevalent on the arms and nape of the patient.

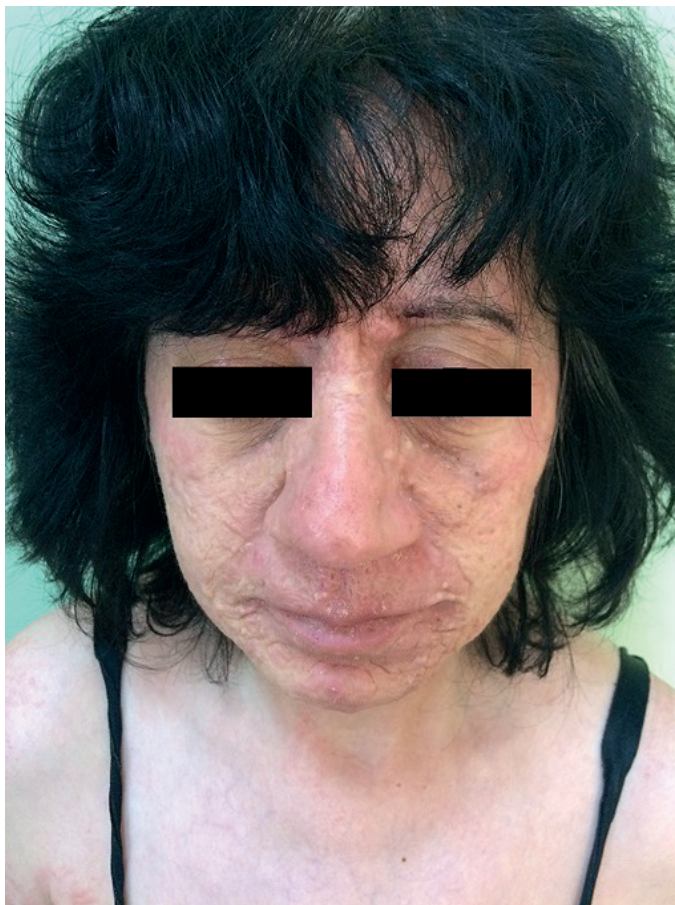

FIGURE 2. Characteristic lion face appearance .

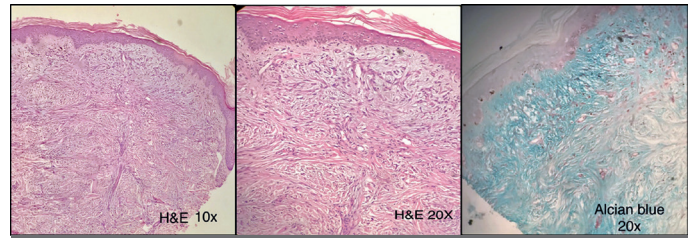


FIGURE 3. Histopathological examination revealed widespread mucin accumulation with alcian and colloidal iron stains in the papillary and reticular dermis .

and nape of the patient (Figure 1). A characteristic lion face appearance was observed (Figure 2). Skin biopsy was taken for the differential diagnosis of the patient.

Histopathological examination revealed widespread mucin accumulation with alcian and colloidal iron stains in the papillary and reticular dermis (Figure 3). Granulomas were not observed with CD68 staining, and no accumulation with amyloid staining was observed. The final diagnosis was cutaneous mucinosis.

The department of hematology was consulted for research on monoclonal gammopathy. The patient’s protein electrophoresis and bone marrow biopsy were normal. Monoclonal gammopathy was not detected. Systematic treatment [such as melphalan, thalidomide, cyclophosphamide, intravenous immunoglobulin (IVIg), and interferon alpha administration; autologous stem cell transplantation and plasmapheresis] was not planned by hematology. Thyroid levels were normal, and the patient was HIV- and HCV-negative.

The patient was treated with oral hydroxychloroquine 200 mg twice daily and topical pimecrolimus cream. The patient is still being followed up at our clinic. Informed consent was obtained from the patient for the publication of this case report and images.

DISCUSSION

Scleromyxedema is also known as generalized lichen myxedematosus (LM). LM is an idiopathic, cutaneous mucinosis with two clinicopathologic subtypes (1). There is the generalized papular and sclerodermoid form, more frequently termed scleromyxedema, and the localized papular form (1). The localized papular form has four variants: a discrete papular form, an acral persistent form, a nodular form, and a papular mucinosis of infancy (2). It is important to distinguish between localized and generalized shapes because the management and prognosis of each differ. Unlike LM, scleromyxedema is associated with sclerosis, paraproteinemia, thyroid disease, or other systemic involvement (1).

The first differential diagnosis for scleromyxedema is scleroderma (3). In particular, the presence of papules in linear arrays is a helpful practical indicator in the differentiation of scleromyxedema. Furthermore, papules not available in scleroderma are disjunctive in scleromyxedema (4). Scleromyxedema differs from other skin mucinosises in terms of four diagnostic findings: generalized papular and sclerodermoid eruption, dermal mucin accumulation with fibroblast proliferation and fibrosis, and monoclonal gammopathy without thyroid disease (5). Systemic mucin deposition may include systemic involvement, monoclonal gammopathy or paraproteinemia have been detected in the

large majority (83.2%) of scleromyxedema cases. Of note, 10% of scleromyxedema cases can develop into multiple myeloma (6). In our case, there was no evidence of any systemic scans.

Scleromyxedema most commonly involves the hand, forearm, head and neck region, the upper part of the torso, and hips; skin thickening in the face can cause a typical lion face appearance (7). In our case, the areas of involvement were similar to those reported in the literature, and a lion face appearance was observed.

In scleromyxedema, widespread mucin accumulation in the upper and middle reticular dermis and an increase in collagen accumulation are histopathologic determinants (8). Similar histopathological findings were observed in our case. Our patient was clinically and histopathologically diagnosed with scleromyxedema.

No certain treatment exists for cutaneous mucinosis. Numerous treatments have been suggested in case reports, particularly for the generalized type. However, scleromyxedema treatment does not usually have a good result. Several treatment options, such as melphalan, IVIG, systemic steroids, oral retinoid, thalidomide, cyclophosphamide, cyclosporine, and methotrexate administration; psoralen and ultraviolet A radiation; plasmapheresis; autologous stem cell transplantation; electron radiotherapy; and extracorporeal photopheresis, have been described in the literature (9). However, in the literature, there is only one case report of hydroxychloroquine treatment in which a series of four cases achieved successful results with the treatment (10). In our case, hydroxychloroquine was utilized as treatment because of its noticed effectiveness in other cutaneous mucinosis cases.

In conclusion, we present the case of a patient with scleromyxedema without concomitant monoclonal gammopathy and draw attention to hydroxychloroquine treatment.

Informed Consent: Written informed consent was obtained from the patient for the publication of this case report and images.

Presented: This study was presented at the 3rd International Dermatology and Cosmetology Congress (INDERCOS) May 14-17, 2018, Istanbul, Turkey.

Peer-review: Externally peer-reviewed.

Author contributions: Concept -S.A.T, R.D., A.A., İ.Ö.; Design -S.A.T., R.D., A.A., İ.Ö.; Supervision - S.A.T., R.D., A.A., İ.Ö., S.F.; Resource - S.A.T., R.D., A.A., İ.Ö., S.F.; Materials - S.A.T., R.D.; Data Collection and/or Processing - S.A.T., R.D., İ.Ö., S.F.; Analysis and/or Interpretation - S.A.T., R.D., A.A., İ.Ö., S.F.; Literature Search - S.A.T., İ.Ö.; Writing -S.A.T., R.D.; Critical Reviews - S.A.T., R.D., A.A., İ.Ö., S.F.

Conflict of Interest: The authors have no conflicts of interest to declare.

Financial Disclosure: The authors declare that this study has received no financial support.

REFERENCES

1. Rongioletti F, Rebora A. Updated classification of papular mucinosis, lichen myxedematosus, and scleromyxedema. *J Am Acad Dermatol* 2001; 44: 273-81. [\[CrossRef\]](#)
2. Rongioletti F. Lichen myxedematosus (papular mucinosis): new concepts and perspectives for an old disease. *Semin Cutan Med Surg* 2006; 25: 100-4. [\[CrossRef\]](#)
3. Popović D, Paravina M, Jovanović D, Karanikolić V, Ljubisavljević D. Scleromyxedema (ArndtGottron Syndrome): a Case Report. *Serbian Journal of Dermatology and Venereology* 2016; 8: 28-38. [\[CrossRef\]](#)
4. Finkel, LJ, Headington JT. Cutaneous mucinosis and amyloidosis. *Dermatology* 1992; 3: 1597-602.
5. Lin YC, Wang HC, Shen JL. Scleromyxedema: An experience using treatment with systemic corticosteroid and review of the published work. *J Dermatol* 2006; 33: 207-10. [\[CrossRef\]](#)
6. Georgakis CDC, Falasca G, Georgakis A, Heymann WR. Scleromyxedema. *Clin Dermatol* 2006; 24: 93-497. [\[CrossRef\]](#)
7. Dinneen AM, Dicken CH. Scleromyxedema. *J Am Acad Dermatol* 1995; 33: 37-43. [\[CrossRef\]](#)
8. Serdar ZA, Altunay IK, Yasar SP, Erfan GT, Güneş P. Generalized papular and sclerodermoid eruption: scleromyxedema. *Indian J Dermatol Venereol Leprol* 2010; 76: 592. [\[CrossRef\]](#)
9. Bidier M, Zschoche C, Gholam P, Enk AH, Hadaschik EN. Scleromyxedema: clinical follow-up after successful treatment with high-dose immunoglobulins reveals different long-term outcomes. *Acta Derm Venereol* 2012; 92: 408-9. [\[CrossRef\]](#)
10. Terheyden P, Becker JC, Lurz C, Kahaly GJ, Bröcker EB. Treatment of scleromyxedema with hydroxychloroquine. *J Dtsch Dermatol Ges* 2003; 1: 30-35. [\[CrossRef\]](#)