

Protective Effect of Nigella Sativa Oil Against Indomethacin-Related Small Intestine and Gastric Mucosal Damage in Rats

Emre Günay¹ , Erkan Özkan¹ , Hacı Hasan Abuoğlu¹ , Aslı Aykaç² , Ayliz Velioglu-Öğünç³ , Buse Karanlık⁴ , Şule Çetinel⁵ , Ahmet Özer Şehirli⁶ 

¹Department of General Surgery, Haydarpaşa Numune Research Hospital, İstanbul, Turkey

²Department of Biophysics, Near East University School of Medicine, Mersin, Turkey

³Department of Biochemistry, Vocational School of Health Related Professions, Marmara University, İstanbul, Turkey

⁴Department of Histology and Embryology, Cyprus Dünya IVF Center, Mersin, Turkey

⁵Department of Histology and Embryology, Marmara University School of Medicine, İstanbul, Turkey

⁶Department of Pharmacology, Near East University School of Dentistry, Mersin, Turkey

ORCID iDs of the authors: E.G. 0000-0003-3445-4935; E.Ö. 0000-0003-2803-1354; H.H.A. 0000-0002-2285-0685; A.A. 0000-0002-4885-5070; A.V.Ö. 0000-0001-8453-6491; B.K. 0000-0002-4181-6837; Ş.Ç. 0000-0003-1912-3679; A.Ö.Ş. 0000-0002-5175-9290.

Cite this article as: Günay E, Özkan E, Abuoğlu HH, Aykaç A, Velioglu Öğünç A, Karanlık B, Çetinel Ş, Şehirli AÖ. Protective Effect of Nigella Sativa Oil Against Indomethacin-Related Small Intestine and Gastric Mucosal Damage in Rats. *Cyprus J Med Sci* 2021; 6(1): 8-12.

BACKGROUND/AIMS

The aim of this study was to investigate the effects of Nigella sativa (NS) oil form on reducing the damage caused by indomethacin in the stomach and duodenum of rats owing to their antioxidant and anti-inflammatory properties.

MATERIAL and METHODS

The rats were divided into 4 groups: group 1, saline-treated control group; group 2, NS-treated control group; group 3, saline-treated ulcer group and ulcers caused by indomethacin (30 mg/kg) and administration of physiological serum; group 4, NS-treated ulcer group, which is the group receiving NS oil after administration of indomethacin. At the end of the study, blood samples collected from animals were examined for tumor necrosis factor alpha (TNF- α), interleukin-1 beta (IL-1 β), and glutathione (GSH), malondialdehyde (MDA) levels and myeloperoxidase (MPO), and Na⁺/K⁺-ATPase activities in gastric and intestinal tissue samples.

RESULTS

Levels of TNF- α and IL-1 β in serum and MDA and MPO values in tissue were found to be higher in the saline-treated ulcer group than in the saline-treated control group. In addition, tissue GSH and Na⁺/K⁺-ATPase levels were found to be lower. These values were found to be reversed when comparing NS-treated ulcer group to saline-treated ulcer group. Histopathological findings showed epithelial regeneration and improvement instead of dense tissue damage.

CONCLUSION

The strong antioxidant and anti-inflammatory effects of NS against potential small intestine and gastric damage were shown using an experimental indomethacin-induced ulcer model in rats. Hence, our study suggests that NS used together with indomethacin can prevent gastrointestinal damage; thus, this agent can create a new clinical therapeutic principle.

Keywords: Indomethacin, Nigella sativa oil, ulcer, glutathione

INTRODUCTION

For the treatment of fever, pain, and inflammation, non-steroidal anti-inflammatory drugs (NSAIDs) are broadly used; however, these drugs lead to severe damage of the gastrointestinal tract. In particular, indomethacin causes an increase in free oxygen radicals and inflammatory cytokine levels through neutrophil infiltration. There are many studies that show that antioxidant parameters decrease and oxidant parameters increase in damaged gastric tissue when treated by indomethacin. In the gastrointestinal tissue of indomethacin-treated animals, myeloperoxidase (MPO) and malondialdehyde (MDA) levels were increased, and antioxidant parameters such as glutathione (GSH) were decreased. Therefore, it is argued that indomethacin ulcers can be treated by increasing the antioxidant effect (1-3) Nigella sativa (NS), also known as black cumin seed, has been used for a long time as a traditional treatment method in India and in the Middle and Far

East subcontinent parts. This ancient spice has been used for centuries by Ayurvedic (i.e., traditional Hindu medicine), Greeks, and herbal medicine practitioners to treat many diseases such as bronchial asthma, infection, gastrointestinal problems, and hypertension (4, 5). The studies have demonstrated that NS extracts show a plurality of therapeutic effects, including antioxidant, hepatoprotective, immunomodulatory, anti-inflammatory, and antitumor effects (6-8).

In our study, the anti-inflammatory and antioxidant properties of the 100% pure oil form of NS and its effect of decreasing the damage caused by indomethacin in the stomach and duodenum are investigated. In particular, gastrointestinal system damage induced by indomethacin restricts its therapeutic property, making it useful for certain symptoms. A similar study using NS has never been carried out previously, and this study could shed light on future experimental and clinical studies.

MATERIAL and METHODS

Animals and Experimental Conditions

Approval from the Ethical Committee (Marmara University Animal Care and Use Committee) was obtained before the current experimental period (Approval number: 26.2011.Mar; Approval date: 26/04/2011). The number of male and female rats that were used in this study was equal. The rats were kept at 12-hour light/dark cycles and at a constant temperature ($21 \pm 3^\circ\text{C}$) with $50 \pm 5\%$ humidity. The rats were fed ad libitum with standardized rat chow and water.

Animal Groups and Treatment

Each group consisted of 8 rats, randomly divided into 4 groups:

- Saline-treated control group: 0.1 mg/kg physiological saline solution was administered perorally.
- NS-treated control group: 10 ml/kg NS oil was given through gavage to rats.
- Saline-treated ulcer group: to induce ulcer, 30 mg/kg indomethacin and physiological saline solution were administered by gavage to rats.
- NS-treated ulcer group: after administering 30 mg/kg indomethacin, 10 ml/kg NS was given by gavage.

All treatments were given daily, at the same time of the day. After 6 hours of administration of indomethacin, all rats were killed. Two cc blood samples were collected from the vena cava.

Main Points:

- Indomethacin has a broad range of uses in rheumatic disorders such as rheumatoid arthritis, ankylosing spondylitis and osteoarthritis, as well as tendonitis and traumatic synovitis, but its gastropathic side effects.
- Indomethacin causes an increase in free oxygen radicals and inflammatory cytokine levels through neutrophil infiltration.
- Nigella sativa oil exerted potent anti-inflammatory and anti-oxidative actions in the serum, tissue, and histological sections of rats with indomethacin-induced gastric and intestinal mucosal damage.

The stomach and duodenum tissue samples were removed and stored at -80°C until starting the current experimental procedure.

Biochemical Analysis

Cytokine assay. To determine tumor necrosis factor alpha (TNF- α) (catalog number: KRC 3014, Biosource Europe SA, Nivelles, Belgium) and interleukin-1 beta (IL-1 β) (catalog number: KRC0011, Biosource Europe SA, Nivelles, Belgium) levels from serum, they were measured by rat specific enzyme-linked immunosorbent assay (ELISA) kits according to manufacturer's protocol. Intra-assay and inter-assay precision for TNF- α were 4.1% and 8.9%, respectively. Intra-assay and inter-assay precision for IL-1 β were 7.5% and 9.3%, respectively.

The Assay of Glutathione (GSH) and Malondialdehyde (MDA) levels and Myeloperoxidase (MPO) and Na^+/K^+ -ATPase activities. In total, 20 mg of the duodenum and stomach tissues was obtained from each rat and then washed in cold phosphate-buffered saline for MDA, MPO, and GSH assay. To determine MDA and GSH levels and MPO and Na^+/K^+ -ATPase activities, commercially available assay kits were used (catalog number: ab11897, ab105136, ab138881, Abcam, Cambridge, UK; catalog number: MBS824 3226, MyBioSource, San Diego, USA, respectively).

Histopathological Analysis

Tissue sections with ulceration were evaluated under a light microscope (Olympus BX 51; Olympus, Shibuya, Tokyo). First, specimens were fixed in 10% formalin and then embedded in paraffin wax. Second, a 5- μm thick section was taken from the specimens. This was followed by hematoxylin and eosin staining.

Statistical Analysis

GraphPad software (Prism 3.0; GraphPad Software, San Diego, CA, USA) was used for statistical evaluation. All data were expressed as means \pm standard error of the mean. GSH and MDA levels, MPO and Na^+/K^+ -ATPase activities in both the stomach and duodenum tissues, and TNF- α and IL-1 β levels in serum between the groups of data were compared pairwise using one-way analysis of variance and Tukey's test.

RESULTS

Biochemical Findings

TNF- α and IL-1 β serum levels were significantly higher in the ulcer group than those in the saline-treated control group ($p < .001$), whereas in the NS-treated ulcer group, those levels were found to be decreased in the ulcer group compared with the levels in the saline-treated control group ($p < .001$) (Table 1).

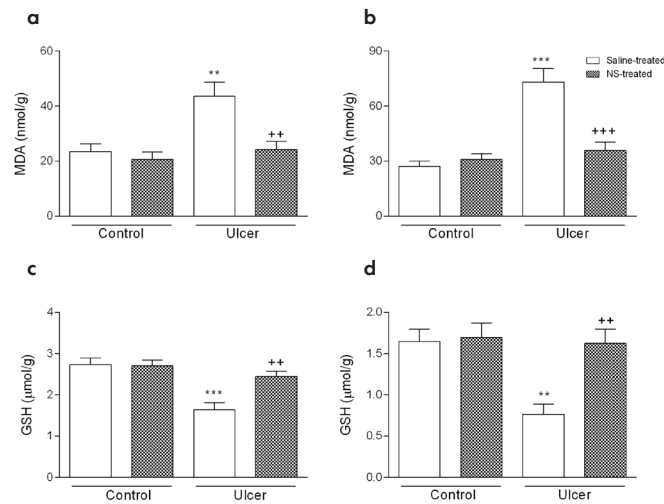
MDA levels in the stomach and duodenum tissues were found to be significantly increased in the saline-treated ulcer group compared with the levels in the saline-treated control group ($p < .01$ and $p < .001$, respectively). Administering NS significantly reduced the increase in MDA levels in both tissues ($p < .01$ and $p < .001$, respectively) (Figures 1a and b).

In the saline-treated ulcer group, GSH levels of the stomach and duodenum tissues were found to be significantly lower than those in the saline-treated control group ($p < .001$ and $p < .01$, re-

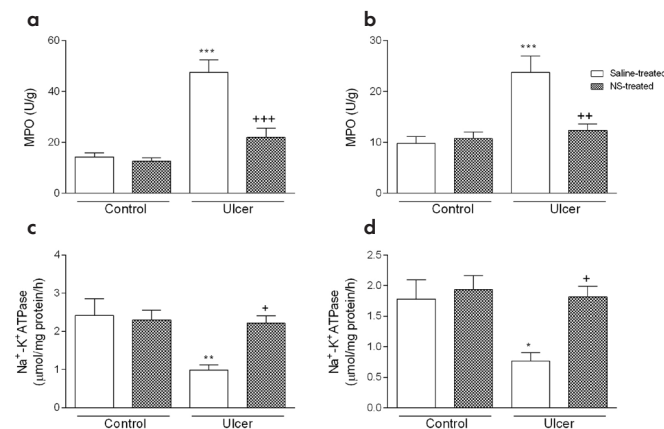
TABLE I. Indomethacin-Induced Ulcer Model in Rats with Serum Levels of TNF- α and IL-1 β in All Groups

	Control		Ulcer	
	Saline-treated	NS-treated	Saline-treated	NS-treated
TNF- α (pg/ml)	793 \pm 2.06	913 \pm 1.66	38.83 \pm 794 ***	13.57 \pm 3.49 ***
IL-1 β (pg/ml)	11.07 \pm 1.70	12.89 \pm 1.87	39.52 \pm 3.15 ***	16.22 \pm 2.78 ***

***, $P < .001$ comparisons of ulcer group to saline group and +, $P < .05$ comparisons of NS-treated ulcer group to ulcer group.
NS: Nigella sativa; TNF- α : tumor necrosis factor alpha; IL-1 β : Interleukin-1 beta

**Figure 1. a-d.** The representative graph showing indomethacin-induced ulcer model in rats in all groups: (a) MDA levels in the stomach, (b) MDA levels in the duodenum, (c) GSH levels in the stomach, and (d) GSH levels in the duodenum.

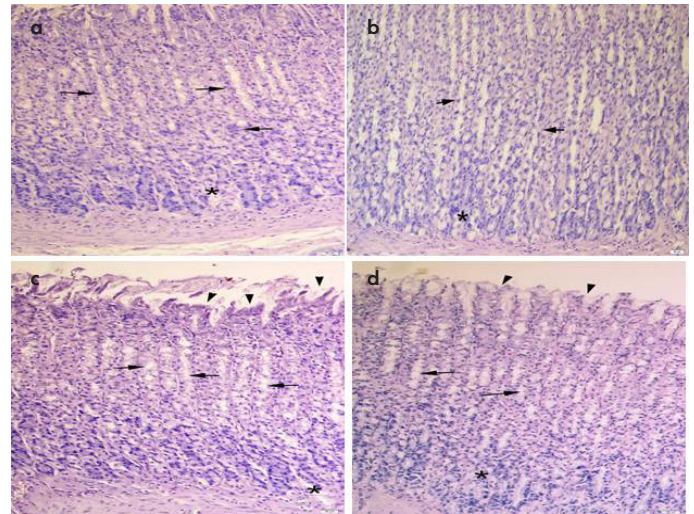
, $P < .01$ and *, $P < .001$ comparisons of saline-treated control group; +, $P < .05$ and +++, $P < .001$ comparisons of saline-treated ulcer group. NS: Nigella Sativa; MDA: Malondialdehyde; GSH: Glutathione

**Figure 2. a-d.** The representative graph showing indomethacin-induced ulcer model in rats in all groups: (a) MPO activity in the stomach, (b) MPO activity in the duodenum, (c) Na⁺/K⁺-ATPase activity in the stomach, and (d) Na⁺/K⁺-ATPase activity in the duodenum.

*, $P < .05$; **, $P < .01$ and ***, $P < .001$ comparisons of saline-treated control group; +, $P < .05$; ++, $P < .01$ and +++, $P < .001$ comparisons of saline-treated ulcer group. NS: Nigella sativa; MPO: Myeloperoxidase

spectively). The decrease has been significantly prevented in the NS-treated ulcer group ($p < .01$) (Figure 1c and d).

The development of ulcers resulted in neutrophil infiltration, leading to a significant increase in the MPO activity in the

**Figure 3. a-d.** (a) Saline-treated control group: regular layout of the epithelial and neck cells (arrows) and the glandular portion (*), (b) NS-treated control group: similar to the saline-treated group in having regular neck cells (arrows) and a glandular portion (*), (c) Saline-treated ulcer group: severe desquamation of epithelial (arrowheads) cells and dilation of the neck (arrows) and the glandular (*) region, (d) NS-treated ulcer group: reduced desquamation of epithelial cells (arrowheads) and dilation of the neck (arrows) and the glandular region (*). Magnification of all pictures are $\times 200$. NS, Nigella sativa

gastric and duodenal tissues compared with the activity in saline-treated control group ($p < .001$). In addition, MPO activity was significantly reduced in the NS-treated ulcer group, which recovered the values close to those of the saline-treated control group ($p < .001$ and $p < .01$, respectively) (Figures 2a and b).

Na⁺/K⁺-ATPase activity in the stomach and duodenal tissues was found to be significantly lower in the saline-treated ulcer group than that in the saline-treated control group ($p < .01$ and $p < .05$, respectively). It was noticed that NS has a significant protective effect in the ulcer group ($p < .05$) (Figure 2c and d).

Histopathological Findings

Stomach. In the stomach, the morphology of neck cells and glandular cells seems to be regular in the saline-treated control group (Figure 3a), and cells in the NS-treated control group have similar morphology (Figure 3b). The saline-treated ulcer group showed severe epithelial desquamation and dilation of the neck region in cells (Figure 3c), whereas in the NS-treated ulcer group, these properties of cells had reduced (Figure 3d).

Duodenum. In the saline-treated control group, the duodenum showed a regular morphology in both epithelium and glands

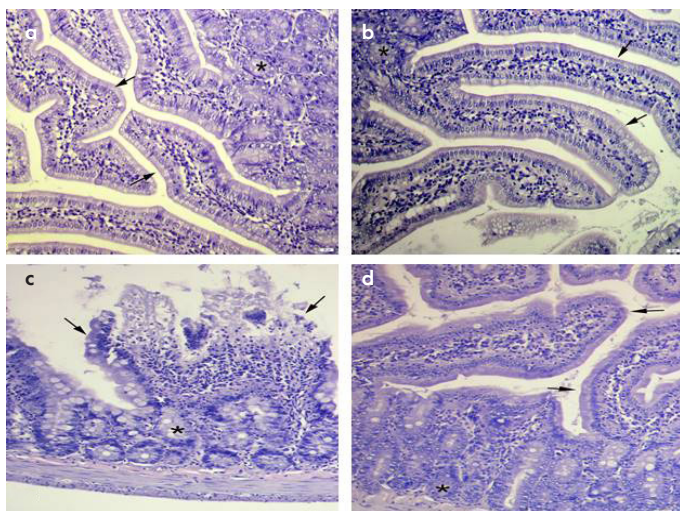


Figure 4. a-d. (a) Saline-treated control group: regular morphology with epithelium (arrows) and glands (*), (b) NS-treated control group: the epithelium (arrows) and the gland (*), (c) Saline-treated ulcer group: severe villar degeneration (arrows) and the gland (*), (d) NS-treated ulcer group: re-epithelization of the villi structure (arrows) and the gland (*). Magnification of all pictures are $\times 200$ NS, *Nigella sativa*

(Figure 4a). In addition, a similar morphology was seen in the NS-treated control group (Figure 4b). The saline-treated ulcer group revealed severe desquamation of villar epithelial and glandular degeneration (Figure 4c), whereas regeneration was prominent in both villar and glandular morphologies in the NS-treated ulcer group (Figure 4d).

DISCUSSION

Indomethacin, a widely used NSAID, exerts adverse effects on the mucosal lining of the gastric and small intestinal wall. Gastrointestinal side effects of indomethacin have been linked to increased production of inflammatory cytokines and neutrophil infiltration, which leads to mucosal injury (9, 10).

Black cumin/seed, also known as NS, has traditionally been used as a remedy by various Middle and Far East folks (11, 13). Studies in rats have demonstrated that NS possesses some potent pulmonary protective, anti-inflammatory, antinephropathic, and anticarcinogenic effects (14-16).

The aim of this study was to investigate the efficacy of the oil form of NS in the prevention of indomethacin-induced gastric mucosal injury in a rat model. This study will provide valuable insight into the antioxidant and anti-inflammatory effects of the oil form of NS in small intestinal and gastric indomethacin-induced mucosal damage. A gastrointestinal inflammatory response caused by NSAIDs may use TNF- α and IL-1 β as the principal signal molecules. Recent studies show that indomethacin-induced ulcer injury in rats is characterized by neutrophil accumulation and increased gastrointestinal circulatory levels of IL-1 β and TNF- α (17-19). We have determined that the levels of TNF- α and IL-1 β in the serum were higher in the ulcer group than those in the saline group. However, administering NS to the ulcer group significantly reduced the levels of TNF- α and IL-1 β , and the levels became similar to those of the saline group values.

The detrimental effects of free oxygen radicals are eliminated by some natural defense mechanisms, including GSH. Previous studies have shown that indomethacin decreases GSH levels in gastrointestinal tissues (20, 21). According to Ersahin et al. (22), NS oil potent free radical scavenging properties acted against reactive hydroxyl, peroxy, and superoxide radicals to counteract lipid peroxidation of the brain tissue caused by a subarachnoid hemorrhage in rats. This effect was carried out by the preservation of the level of the antioxidant GSH (22). We revealed a significant reduction in GSH levels in the stomach and duodenal tissues in the ulcer group compared with those in the saline group. In addition, it has been found that NS could avert this reduction to a significant degree. These compounds lead to the denaturation of intracellular enzymes and proteins, worsening tissue injury. Thus, it has been proposed that lipid peroxidation can be accurately reflected by MDA levels (23). In this study, significantly higher MDA levels in the stomach and duodenal tissues were found in the indomethacin-induced ulcer group than those in the saline group. On the other hand, NS treatment reduced MDA levels significantly. Normal neutrophil functions depend on MPO, which is produced by hydrochloric acid as a product of neutrophil oxidation. MPO levels are increased by neutrophils stimulation caused by various stimuli such as indomethacin (23). Yildiz et al. (24) showed that ischemia-reperfusion injury induced in rat liver created enhanced lipid peroxidation and inflammatory response. As a result, this leads to increased MPO levels, which were then reduced by the administration of NS (24). We found out that the indomethacin-induced ulcer group had significantly higher MPO levels in gastric and duodenal tissues than the control group, and this effect was significantly reversed by NS.

Na^+/K^+ -ATPase is a vital enzyme for cellular functions that acts by maintaining membrane potential and cellular osmotic balance. Its function is sensitive and profoundly impaired by free radicals and reactive oxygen species for the transport of proteins. The red blood cell membrane is exposed to lipid peroxidation by the action of oxidative stress, culminating in alterations in membrane lipid content. This gives rise to reduced membrane fluidity and Na^+/K^+ -ATPase activity in the red blood cell membrane (25, 26). According to our results, the ulcer group had a significantly lower Na^+/K^+ -ATPase activity in the gastric and duodenal tissues than in the control group, and this effect was largely eliminated by NS. It has been shown that the inflammatory and histopathological analyses revealed a wide-scale indomethacin-induced gastric tissue injury involving gastric epithelial cells and glandular cells, which included mainly vacuolization and was relieved in the form of epithelial regeneration and improvement after NS administration.

Our results suggest that NS oil exerted potent anti-inflammatory and antioxidative actions in the serum, tissue, and histological sections of rats with indomethacin-induced gastric and intestinal mucosal damage.

Indomethacin has a broad range of uses in rheumatic disorders such as rheumatoid arthritis, ankylosing spondylitis, and osteoarthritis, as well as tendonitis and traumatic synovitis. Unfortunately, its gastropathy side effects may preclude its use in these disorders. NS offers hope in this regard and may be used in con-

junction with indomethacin to overcome its detrimental gastric side effects. Our study is the first to explore this possibility, and further studies are needed to clarify this issue.

Ethics Committee Approval: Ethics committee approval was received for this study from Marmara University Experimental Animal Research Centre (The approval code (registration number) is 26.2011.Mar and the approval date is 14/04/2011.).

Informed Consent: N/A

Peer-review: Externally peer-reviewed.

Author contributions: Concept - E.G., E.Ö., H.H.A., A.Ö.Ş.; Design - E.G., A.Ö.Ş.; Supervision - E.G., A.Ö.Ş.; Resource - E.G., E.Ö., H.H.A., A.Ö.Ş.; Materials - E.G., E.Ö., H.H.A., A.Ö.Ş.; Data Collection and/or Processing - A.Ö.Ş., A.V.Ö., A.A., Ş.Ç.; Analysis and/or Interpretation - A.V.Ö., A.Ö.Ş., Ş.Ç.; Literature Search - A.A., B.K.; Writing - E.G., A.A., B.K., A.Ö.Ş.; Critical Reviews - E.G., A.Ö.Ş.

Conflict of Interest: The authors have no conflicts of interest to declare.

Financial Disclosure: The author declared that this study has received no financial support.

REFERENCES

- Gong J, Zhang Z, Zhang X, Chen F, Tan Y, Li H, Jiang J, et al. Effects and possible mechanisms of *Alpinia officinarum* ethanol extract on indomethacin-induced gastric injury in rats. *Pharm Biol* 2018; 56(1): 294-301. [\[Crossref\]](#)
- Higuchi K, Umegaki E, Watanabe T, Yoda Y, Morita E, Murano M. Present status and strategy of NSAIDs-induced small bowel injury. *J Gastroenterol* 2009; 44(9): 879-88. [\[Crossref\]](#)
- Higuchi K, Yoda Y, Amagase K, Kato S, Tokioka S, Murano M. Prevention of NSAID-induced small intestinal mucosal injury: Prophylactic potential of lansoprazol. *J Clin Biochem Nutr* 2009; 45(2): 125-30. [\[Crossref\]](#)
- Al-Rowais NA. Herbal medicine in the treatment of diabetes mellitus. *Saudi Med J* 2002; 23(11): 1327-31.
- Arslan SO, Gelir E, Armutcu F, Coskun O, Gurel A, Sayan H. The protective effect of thymoquinone on ethanol-induced acute gastric damage in the rats. *Nutrit Res* 2005; 25: 673-80. [\[Crossref\]](#)
- Kanter M, Coskun O, Budancamanak M. Hepatoprotective effects of nigella sativa I and urticadioica I on lipid peroxidation, antioxidant enzyme systems and liver enzymes in carbontetrachloride-treated rats. *World J Gastroenterol* 2005; 11(42): 6684-8. [\[Crossref\]](#)
- El-Kadi A, Kandil O. The black seed (*Nigella sativa*) and immunity: its effect on human T cell subset. *Fed Proc* 1987; 46: 1222.
- Salem ML. Immunomodulatory and antitumor effects of simultaneous treatment of mice with n-3 and n-6 polyunsaturated fatty acids. *J Union Arab Biol* 2000; 14: 489-505.
- Erkin B, Dokmeci D, Altaner S, Turan FN. Gastroprotective effect of L-carnitine on indomethacin-induced gastric mucosal injury in rats: a preliminary study. *Folia Med (Plovdiv)* 2006; 48(3-4): 86-9.
- Kato S, Takeuchi K. Alteration of gastric ulcerogenic and healing responses in rats with adjuvant-induced arthritis. *Jpn J Pharmacol* 2002; 89(1): 1-6. [\[Crossref\]](#)
- Cotton PB, Shorvon PJ. Analysis of endoscopy and radiography in the diagnosis, follow-up and treatment of peptic ulcer disease. *Clin Gastroenterol* 1984; 13(2): 383-403.
- Butt UJ, Shah SAA, Ahmed T, Zahid S. Protective effects of *Nigella sativa* L. seed extract on lead induced neurotoxicity during development and early life in mouse models. *Toxicol Res (Camb)* 2017; 7(1): 32-40. [\[Crossref\]](#)
- Ismail M, Al-Naqeeq G, Chan KW. *Nigella sativa* thymoquinone-rich fraction greatly improves plasma antioxidant capacity and expression of antioxidant genes in hypercholesterolemic rats. *Free Rad Biol Med* 2010; 48(5): 664-72. [\[Crossref\]](#)
- Al Mofleh IA, Abdulqader A, Mossa AJS, Al-Sohaibani MO, Al-Yahya MA, Rafatullah S, et al. Gastroprotective Effect of an Aqueous Suspension of Black Cumin *Nigella sativa* on Necrotizing Agents-Induced Gastric Injury in Experimental Animals. *Saudi J Gastroenterol* 2008; 14(3): 128-34. [\[Crossref\]](#)
- Tayman C, Cekmez F, Kafa IM, Canpolat FE, Cetinkaya M, Tonbul A, et al. Protective Effects of *Nigella sativa* Oil in Hyperoxia-Induced Lung Injury. *Arch Bronconeumol* 2013; 49(1): 15-21. [\[Crossref\]](#)
- Havakhah S, Sadeghnia HR, Hajzadeh M-A-R, Roshan NM, Shafiee S, Hosseinzadeh H, et al. Effect of *Nigella sativa* on ischemia-reperfusion induced rat kidney damage. *Iran J Basic Med Sci* 2014; 17(12): 986-92.
- Abbas AM Sakr HF. Effect of selenium and grape seed extract on indomethacin-induced gastric ulcers in rats. *J Physiol Biochem* 2013; 69(3): 527-37. [\[Crossref\]](#)
- Santucci L, Fiorucci S, Giansanti M, Brunori PM, Di Matteo FM, Morrelli A. Pentoxifylline prevents indomethacin induced acute gastric mucosal damage in rats. role of tumour necrosis factor alpha. *Gut* 1994; 35(7): 909-15. [\[Crossref\]](#)
- Ding SZ, Lam SK, Yuen ST, Wong BC, Hui WM, Ho J, et al. Prostaglandin, tumor necrosis factor alpha and neutrophils: causative relationship in indomethacin-induced stomach injuries. *Eur J Pharmacol* 1998; 348(2-3): 257-63. [\[Crossref\]](#)
- Sayed DA, Soliman AM, Fahmy SR. Echinochrome pigment as novel therapeutic agent against experimentally - induced gastric ulcer in rats. *Biomed Pharmacother* 2018; 107: 90-5. [\[Crossref\]](#)
- Tastekin E, Ayvaz S, Usta U, Aydogdu N, Cancilar E, Puyan FO. Indomethacin-induced gastric damage in rats and the protective effect of donkey milk. *Arch Med Sci* 2018; 14(3): 671-8. [\[Crossref\]](#)
- Erşahin M, Toklu HZ, Akakin D, Yuksel M, Yegen BC, Sener G. The effects of *Nigella sativa* against oxidative injury in a rat model of subarachnoid hemorrhage. *Acta Neurochirurgica* 2011; 153(2): 333-41. [\[Crossref\]](#)
- Hegab II, Nagi Abd-Ellatif R, Sadek MT. The Gastroprotective Effect of N-acetylcysteine and Genistein in Indomethacin-Induced Gastric Injury in Rats. *Can J Physiol Pharmacol* 2018; 96(11): 1161-70. [\[Crossref\]](#)
- Yildiz F, Coban S, Terzi A, Ates M, Aksoy N, Cakir H, et al. *Nigella sativa* relieves the deleterious effects of ischemia reperfusion injury on liver. *World J Gastroenterol* 2008; 14(33): 5204-9. [\[Crossref\]](#)
- Ozkan E, Yardimci S, Dulundu E, Topaloglu U, Sehirli O, Ercan F, et al. Protective potential of montelukast against hepatic ischemia/reperfusion injury in rats. *J Surg Res* 2010; 159(1): 588-94. [\[Crossref\]](#)
- Konukoglu D, Kemerli GD, Sabuncu T, Hatemi H. Relation of erythrocyte Na⁺-K⁺ ATPase activity and cholesterol and oxidative stress in patients with type 2 diabetes mellitus. *Clin Invest Med* 2003; 26(6): 279-84.