

# Percutaneous Mitral Cleft Repair with MitraClip: An Interesting Case of Owl Eye Appearance in the Mitral Valve

© Cenk Conkbayır<sup>1,2</sup>, © İsmail Ateş<sup>3</sup>, © Alptekin Özkoç<sup>2</sup>

<sup>1</sup>Department of Cardiology, Cyprus Health and Social Sciences University, Güzelyurt, North Cyprus

<sup>2</sup>Clinic of Cardiology, Dr. Burhan Nalbantoğlu State Hospital, Nicosia, North Cyprus

<sup>3</sup>Clinic of Cardiology, İstanbul Şişli Kolan Hospital, İstanbul, Türkiye

## Abstract

We present a case of a successful MitraClip procedure in a 73-year-old male patient with severe mitral regurgitation and an intriguing “owl eye” appearance of the mitral valve. The patient had a history of coronary artery bypass graft surgery ten years previously and experienced recurrent pulmonary edema due to regurgitation. Following the MitraClip procedure, the patient’s symptoms improved, and his quality of life significantly increased.

**Keywords:** Coronary surgery, mitraclip, mitral regurgitation, owl eye

## INTRODUCTION

The aim of this case report was to describe a successful MitraClip procedure in a 73-year-old male patient with a history of coronary artery bypass graft surgery (CABG) and recurrent pulmonary edema caused by severe mitral regurgitation with a cleft in the mitral valve.

## CASE PRESENTATION

A 73-year-old male patient presented to the emergency room with shortness of breath, dyspnea, and orthopnea. Physical examination revealed an S3 gallop, a severe pansystolic murmur, and crackles in the upper lung fields. The patient’s history included recurrent pulmonary edema, reduced quality of life, and chronic obstructive pulmonary disease (COPD) treated with bronchodilators. Echocardiography showed an enlarged left atrium, moderate left ventricular dysfunction [ejection fraction (EF): 40%], and severe mitral regurgitation. Transesophageal echocardiography (TEE) further identified a mitral cleft on the posterior mitral valve. Coronary angiography revealed severe stenotic lesions in the left anterior descending, circumflex, and right coronary arteries, while the saphenous and left internal mammary artery (LIMA) bypass grafts were patent.

Given the patient’s history of CABG, patent bypass grafts, COPD, frequent hospital admissions due to pulmonary edema, and high EuroSCORE (calculated as 14), the heart team recommended a high-risk MitraClip procedure instead of redo open-heart surgery. Informed consent was obtained from the patient and his family after a detailed discussion of the procedure and its associated risks.

Preoperative preparation included the administration of intravenous diuretics, bronchodilators, and oxygen to minimize cardiac and pulmonary-related risks. The patient was placed under general anesthesia and intubated for the MitraClip procedure. A 7-French sheath was inserted, followed by a septostomy performed 3.7 cm away from the mitral valve in order to optimize the entrance of the left atrium and enhance the success of the MitraClip procedure. Under three-dimensional TEE guidance, two MitraClips were successfully inserted, providing an intriguing “owl eye” view of the mitral valve, as demonstrated by 3D echocardiography (Figure 1). Color Doppler imaging revealed mild mitral regurgitation, while X-ray imaging confirmed the presence of the MitraClips (Figure 2). The severe mitral regurgitation (Figure 3) was effectively treated with two MitraClips, as evidenced by mild mitral regurgitation on 2D echocardiography post-procedure

**To cite this article:** Conkbayır C, Ateş İ, Özkoç A. Percutaneous Mitral Cleft Repair with MitraClip: An Interesting Case of Owl Eye Appearance in the Mitral Valve. Cyprus J Med Sci 2024;9(1):73-75

**ORCID IDs of the authors:** C.C. 0000-0002-6594-1915; İ.A. 0000 0003 4921 5582; A.Ö. 0000 0001 8704 9875.



**Address for Correspondence:** Cenk Conkbayır

**E-mail:** cenkconk@hotmail.com

**ORCID ID:** orcid.org/0000-0002-6594-1915

**Received:** 16.11.2022

**Accepted:** 12.07.2023



Copyright © 2024 The Author. Published by Galenos Publishing House on behalf of Cyprus Turkish Medical Association.

This is an open access article under the Creative Commons Attribution-NonCommercial 4.0 International (CC BY-NC 4.0) License.

(Figure 4). Post-procedure, the patient’s symptoms improved, he was extubated, and subsequently discharged. Follow-up revealed no cardiac or lung-related issues, and the patient’s quality of life significantly improved.

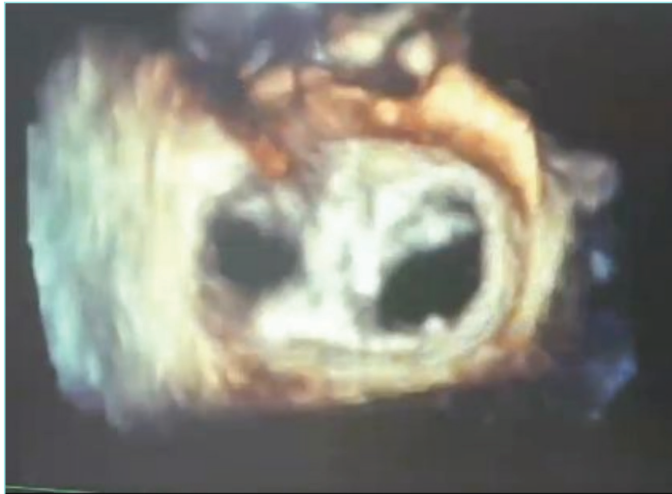**DISCUSSION**

Patients with severe mitral regurgitation and additional risk factors, including advanced age, COPD, prior CABG surgery, low EF, and high EuroSCOREs, face a significant risk of mortality and a diminished

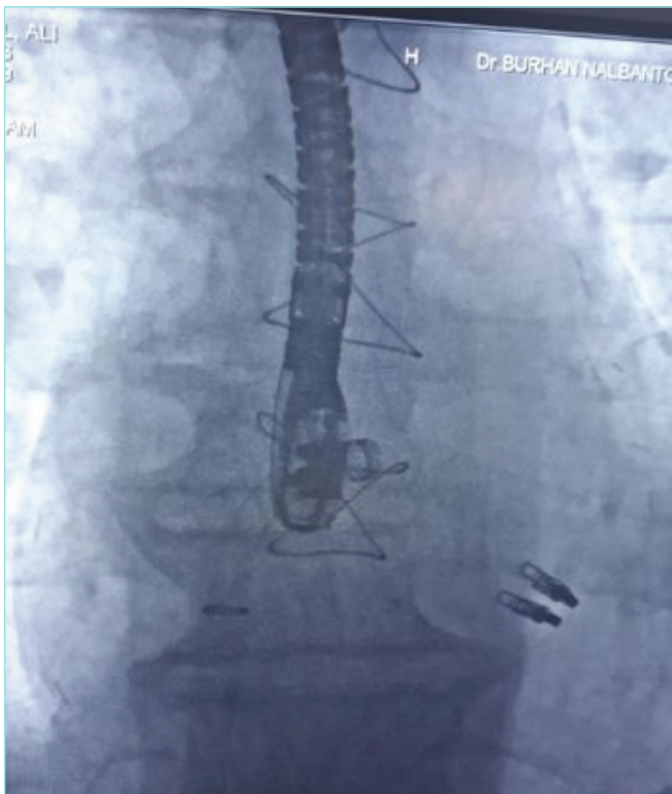quality of life.<sup>1,2</sup> In cases where there is a history of prior CABG surgery with patent LIMA, cardiac surgeons may be hesitant to perform a redo sternotomy due to potential complications and the risk of injuring the LIMA, which can adhere to the sternum due to fibrotic changes between the pericardium and sternum. Conversely, anesthesiologists may be concerned about respiratory complications in COPD patients during the peri- and post-procedural periods. However, with recent advancements in percutaneous mitral valve procedures such as the MitraClip, success rates are increasing as has been shown in a recent meta-analysis where both surgery and MitraClip demonstrated a similar safety profile and shorter length of stay in high-risk patients.<sup>1</sup> The literature has also demonstrated that percutaneous mitral valve clip repair may offer a survival benefit, especially within the initial 1 to 2 years, particularly in those patients with medically managed chronic functional mitral regurgitation.<sup>2,3</sup> Additionally, studies have shown that the MitraClip procedure is both effective and safe in randomized multicenter studies.<sup>3,4</sup> The literature has also discussed “the surgical double orifice technique”, which can provide an “owl eye” view similar to that achieved with the percutaneous MitraClip procedure performed in our case, in cases of severe mitral valve regurgitation.<sup>5</sup>

**CONCLUSION**

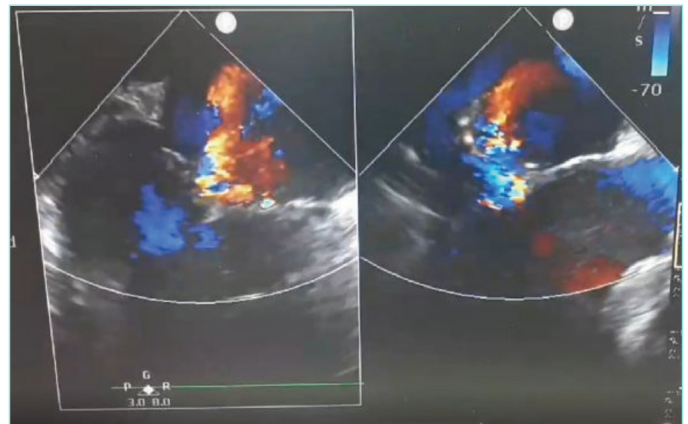
This case report highlights a successful percutaneous mitral valve repair with MitraClip in a high-risk patient with severe mitral regurgitation and a unique “owl eye” appearance of the mitral valve. The procedure



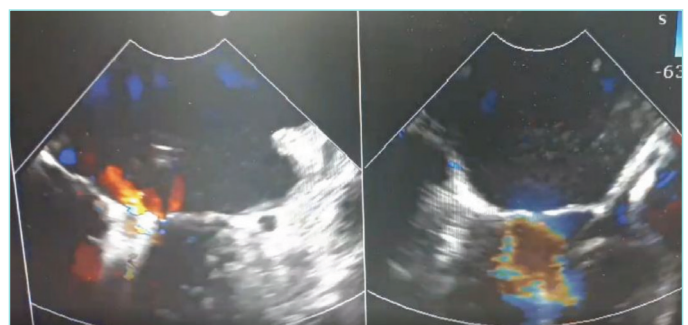
**Figure 1.** “Owl eye” appearance after MitraClip procedure, visualized with 3D transesophageal echocardiography.



**Figure 2.** X-ray image showing the presence of MitraClips.



**Figure 3.** Pre-procedural image illustrating severe mitral regurgitation.



**Figure 4.** Post-procedural image depicting mild mitral regurgitation following MitraClip intervention.

provided significant symptomatic relief and improved the patient's quality of life. Percutaneous mitral valve repair should be considered as a viable option in carefully selected patients, especially those with significant comorbidities or previous cardiac surgeries.

### MAIN POINTS

- The MitraClip procedure provided significant symptomatic relief and improved the patient's quality of life.
- Percutaneous mitral valve repair should be considered as a viable option in carefully selected patients, especially those with significant comorbidities or previous cardiac surgeries.
- We present an interesting case of mitral valve repair with MitraClip in a high-risk patient with severe mitral regurgitation and a unique "owl eye" appearance of the mitral valve.

### ETHICS

**Informed Consent:** Informed consent was obtained from the patient.

### Authorship Contributions

Surgical and Medical Practices: C.C., İ.A., A.Ö., Concept: C.C., İ.A., A.Ö., Design: C.C., İ.A., A.Ö., Data Collection and/or Processing: C.C., İ.A., A.Ö., Analysis and/or Interpretation: C.C., İ.A., A.Ö., Literature Search: C.C., İ.A., A.Ö., Writing: C.C., İ.A., A.Ö.

### DISCLOSURES

**Conflict of Interest:** The authors have no conflicts of interest to declare.

**Financial Disclosure:** The authors declared that this study has received no financial support.

### REFERENCES

1. Oh NA, Kampaktsis PN, Gallo M, Guariento A, Weixler V, Staffa SJ, et al. Doulamis An updated meta-analysis of MitraClip versus surgery for mitral regurgitation. *Ann Cardiothorac Surg.* 2021; 10(1): 1-14.
2. Ansari MT, Ahmadzai N, Coyle K, Coyle D, Moher D. Mitral Valve Clip for Treatment of Mitral Regurgitation: An Evidence-Based Analysis. *Ont Health Technol Assess Ser.* 2015; 15(12): 1-104.
3. Mauri L, Foster E, Glower DD, Apruzzese P, Massaro JM, Herrmann HC, et al. EVEREST II Investigators. 4-year results of a randomized controlled trial of percutaneous repair versus surgery for mitral regurgitation. *J Am Coll Cardiol.* 2013; 62(4) 317-28.
4. Marmagkiolis K, Hakeem A, Ebersole DG, Iliescu C, Ates I, Cilingiroglu M. Clinical outcomes of percutaneous mitral valve repair with MitraClip for the management of functional mitral regurgitation. *Catheter Cardiovasc Interv.* 2019; 94(6) 820-6.
5. Maisano F, Schreuder JJ, Oppizzi M, Fiorani B, Fino C, Alfieri O. The double-orifice technique as a standardized approach to treat mitral regurgitation due to severe myxomatous disease: Surgical technique. *Eur J Cardiothorac Surg.* 2000; 17(3): 201-5.