

Histological, Biochemical and Genetic Investigation of Liver Aging in Rats

Yasin Ali Hassan¹, Gamze Kocamaz², Gülten Tuncel³, Meliha Temizel⁴, Gözde Ögütçü¹, Oğuzhan Edebal⁵,
Tülin Fırat⁶, Aysel Kükner¹

¹Department of Histology and Embryology, Near East University Faculty of Medicine, Nicosia, North Cyprus

²Department of Histology Laboratory, Near East University Faculty of Veterinary Medicine, Nicosia, North Cyprus

³DESAM Research Institute, Near East University, Nicosia, North Cyprus

⁴Experimental Animals Research Centre, Near East University Faculty of Veterinary Medicine, Nicosia, North Cyprus

⁵Department of Biochemistry Laboratory, Near East University Hospital, Nicosia, North Cyprus

⁶Department of Histology and Embryology, Bolu Abant İzzet Baysal University Faculty of Medicine, Bolu, Türkiye

Abstract

BACKGROUND/AIMS: Aging is a chronic, complex and irreversible process that leads to functional deterioration in cells. Structural and functional changes occur in the liver during aging. This study aimed to determine age-related changes in rat liver tissue using histological, biochemical, and gene-expression analyses.

MATERIALS AND METHODS: Wistar albino male rats were used in the study; two groups were formed: a young group (10 weeks) and an aged group (18 months). Blood and tissue samples were collected from the subjects while they were under general anesthesia. Liver enzymes were measured in blood samples. Gene expression levels of interleukin-6 (IL-6), nuclear factor kappa B (NF-kB), mammalian target of rapamycin (mTOR) protein complex, and caspase-3 (Cas-3) in liver tissues were evaluated by real-time polymerase chain reaction following total ribonucleic acid isolation and complementary DNA synthesis. Histological scoring was performed on tissues from the groups. Tissues were evaluated with hematoxylin-eosin, Masson's trichrome, periodic acid-Schiff, and Ki-67 proliferation index stains.

RESULTS: Biochemically, significant increases in cholesterol, triglycerides, alanine transaminase, and alkaline phosphatase were observed in the aged group. Light microscopic examination revealed an increased number of Ki-67-positive and binucleated hepatocytes, vacuolization, sinusoidal congestion, bile-duct proliferation, and increased collagen in the aged group. While *Cas-3* and *mTOR* gene expression increased significantly in the aged group, no differences were observed in IL-6 and NF-kB levels.

CONCLUSION: Histological, apoptotic, and autophagic changes have been observed during physiological aging, and they are known to influence liver function.

Keywords: Aging, liver, Cas-3, mTOR, IL-6, NF-kB

To cite this article: Hassan YA, Kocamaz G, Tuncel G, Temizel M, Ögütçü G, Edebal O, et al. Histological, biochemical and genetic investigation of liver aging in rats. Cyprus J Med Sci. 2026;11(2):176-181

ORCID IDs of the authors: Y.A.H. 0009-0001-7779-8183; G.K. 0000-0001-9092-3949; G.T. 0000-0002-3332-471X; M.T. 0000-0001-7197-1726; G.Ö. 0000-0002-3381-5543; O.E. 0000-0002-3406-6927; T.F. 0000-0002-8317-7092; A.K. 0000-0001-5387-2628.



Corresponding author: Aysel Kükner
E-mail: aysel.kukner@neu.edu.tr
ORCID ID: orcid.org/0000-0001-5387-2628

Received: 04.06.2025
Accepted: 08.12.2025
Epub: 14.01.2026
Publication Date: 22.04.2026



Copyright © 2026 The Author(s). Published by Galenos Publishing House on behalf of Cyprus Turkish Medical Association.
This is an open access article under the Creative Commons AttributionNonCommercial 4.0 International (CC BY-NC 4.0) License.

INTRODUCTION

Cellular senescence is a stress response that links degenerative and hyperplastic pathologies. Aging occurs in diverse cell types throughout the body, and these cells secrete numerous biologically active factors that cause physiological and pathological effects.¹⁻⁴ It is an important risk factor for the development of both acute and chronic liver disease, causing changes in all hepatic cell types, altering their phenotype and function, and worsening disease prognosis. Accordingly, increasing attention has been directed toward developing new therapeutic strategies to prevent or ameliorate age-related hepatic disorders.⁵ The aging liver shows many structural and functional changes: its size decreases by approximately 20-40%; endothelial fenestration decreases; and hepatic blood flow and bile acid secretion by hepatocytes decrease. Decreased numbers of smooth endoplasmic reticulum and mitochondria in hepatocytes, together with high triglyceride levels, trigger the formation of non-alcoholic fatty liver disease.

There is an age-related increase in hepatocyte size and the appearance of polyploid (binucleated) cells. In humans, polyploid cells constitute 6%-15% of hepatocytes in adults aged 20 years, and 25%-42% of hepatocytes in adults aged 80 years. In this context, polyploidy is considered a sign of cellular aging and stress.⁶

Reduced autophagic activity in hepatocytes increases lipid accumulation and promotes hepatic steatosis.⁷ Therefore, activating and regulating autophagy may be a promising strategy to prevent age-related hepatic steatosis by reducing lipid accumulation.^{7,8} Other factors observed in liver aging include apoptosis due to oxidative stress, increased caspase activity, decreased antioxidant capacity, and mitochondrial dysfunction.^{9,10} Activation of a significant number of inflammatory cells (neutrophils and macrophages) and increased inflammatory cytokine levels lead to inflammation and liver fibrosis.^{11,12}

The aim of the present study was to determine the differences in liver tissue at the histological, biochemical, and molecular levels between young and aged rats. Simultaneously, determination of apoptotic caspase-3 (Cas-3), proliferation-associated Ki-67, autophagy-associated mammalian target of rapamycin (mTOR), and inflammation-associated interleukin-6 (IL-6) and *nuclear factor kappa B (NF-κB)* gene expression will be important in defining biological activities involved in the development of age-related changes in the liver.

MATERIALS AND METHODS

In this research, a total of 12 male Albino Wistar rats in total with an average weight of 235-740 gr were provided from Experimental Animals Research Center. The protocols are based on animal experiments approved by the Near East University Experimental Animals and Research Centre Ethics Committee of Research and Application Center (approval number: 2024/175, date: 18.04.2024).

All rats were housed in conventional cages and maintained under the same environmental and nutritional conditions (22±10 °C), with ad libitum access to water and food. Regarding age, rats were divided into two groups: a young group (n=6) consisting of 10-week-old rats, and an aged group (n=6) consisting of 18-month-old rats.

The body weights of the rats were recorded at the beginning and end of the experiment. Ketamine/xylazine anesthesia was administered; intracardiac blood was collected; the liver was removed and weighed. All liver tissue samples were taken from the right lobe.

Histological Analyses

Liver tissues were fixed in 10% neutral formaldehyde solution for histological preparations. Tissues dehydrated in a graded alcohol series were cleared and embedded in paraffin. Thin sections (4-5 μm) were prepared from paraffin blocks and stained with hematoxylin-eosin (Merck, USA), Masson's trichrome (Bio-Optica, Milan, Italy), and periodic acid-Schiff (PAS) (Bio-Optica, Milan, Italy) for microscopic examination. Ki-67 immunohistochemical staining was performed to evaluate proliferation in hepatocytes. Histological scoring of liver tissue from each rat in each group was performed for inflammation, necrosis, fibrosis, and bile duct proliferation in five areas at ×40 objective magnification. Changes were evaluated as 0 (no change), 1 (mild change, <25%), 2 (moderate change, 25-50%), and 3 (severe change, >50%).¹³ Similarly, binucleated hepatocytes and Ki-67-positive hepatocytes were counted in 10 fields per preparation.

Ki-67 Immunohistochemical Analysis

Formaldehyde-fixed tissue was embedded in paraffin for immunohistochemical examination. Sections were deparaffinized in xylene and passed through a descending series of alcohols. Antigen retrieval was performed in citrate buffer (pH 6.0) in a microwave oven at 700 W for 15 minutes. Sections were allowed to cool to room temperature for 30 minutes and were washed twice in phosphate-buffered saline (PBS) for 5 minutes. Endogenous peroxidase was blocked with 3% hydrogen peroxide for 7 minutes. The washed samples were incubated in Ultra V Block for 8 minutes. Blocking solution was removed from the sections, which were then incubated overnight at 4 °C with the primary antibody. Ki-67 was evaluated using Rabbit Polyclonal Antibody, Ready-to-Use (Cat. #RB-9043-R7, Thermo Scientific, USA). After washing the sections in PBS, the secondary antibody was applied for 20 minutes. The sections were washed in PBS twice for 5 minutes each and then incubated with streptavidin-peroxidase for 20 minutes. Sections washed with PBS were incubated with the 3,3'-diaminobenzidine chromogen. Counterstaining with hematoxylin was applied, and after washing, the preparations were mounted.

Biochemical Analyses

The enzyme activities of aspartate aminotransferase (AST), alanine transaminase (ALT) and alkaline phosphatase (ALP) as well as the levels of cholesterol and triglycerides were measured enzymatically on the Abbott Architect c400 system (Abbott Laboratories, IL, USA).

Genetic Analysis

Liver tissues taken for messenger RNA (mRNA) expression analysis of selected genes were stored in dry Eppendorf tubes at -20 °C until nucleic acid isolation. Trizol reagent (Hibrizol, Hibrigen, İstanbul, Türkiye) was used for ribonucleic acid (RNA) isolation. For each sample, 500 ng of RNA was used to synthesize complementary DNA (cDNA) using the ABM first-strand cDNA synthesis kit, according to the manufacturer's instructions. Reference mRNA sequences for the rat *NF-κB*, *IL-6*, *Casp3*, and *mTOR* genes, and for the housekeeping gene *glyceraldehyde 3-phosphate dehydrogenase (GAPDH)*, obtained from the National Center for Biotechnology Information Nucleotide Database, were used to design gene-specific primers. After primer optimization, the expression levels of NF-κB, IL-6, Casp3, mTOR, and GAPDH were evaluated using AMPIGENE® qPCR Green Mix Lo-ROX (ENZO Life Sciences Inc., Lausen, Switzerland) and gene-specific primers on the *Rotor-Gene Q* Plex real-time polymerase chain reaction system (Qiagen, Hilden, Germany). cDNA was diluted tenfold for use as template, with each sample

analysed in triplicate. Normalization of Ct values was carried out using the reference gene, and the comparative $\Delta\Delta Ct$ method was applied to evaluate relative gene expression changes between the two groups.

Statistical Analysis

The results were statistically evaluated using the GraphPad Prism 8.3.1 program. Differences among the groups were analyzed using one-way ANOVA. A significance threshold of $p \leq 0.05$ was used, and standard errors were reported as \pm (value not specified).

RESULTS

Body and Liver Weights

The change in body weight differed significantly between the aged and young groups, with the 18-month-old group having more than twice the body weight of the 10-week-old group ($p < 0.05$). No significant difference was observed in liver weights between young and old groups.

Biochemical Results

Changes in lipid profile and liver enzyme levels, which are indicators of metabolic and physiological alterations that occur with aging, were observed between the two groups. In the elderly group, cholesterol ($p < 0.001$), triglycerides ($p < 0.05$), and the liver enzymes ALT ($p < 0.01$) and ALP ($p < 0.05$) were significantly higher than in the young group. Changes in AST enzyme levels, on the other hand, were not statistically significant (Figure 1).

Histological Results

Age-related changes in the frequency of binucleated hepatocytes were observed in the study groups (Figures 2a and 2b). Binucleated hepatocytes were counted at 40x magnification. While the number was 4.967 ± 2.178 in the 10-week group, it increased to 8.433 ± 3.734 in the 18-month group. This increase was statistically significant ($p < 0.0001$) (Figure 2c). The number of Ki-67-positive hepatocytes was higher in the young group than in the aged group ($p < 0.01$) (Figures 3a-c).

In histological scoring, a significant increase in congestion, vacuolization, fibrosis, and bile duct proliferation was observed in the aged group compared with the young group, whereas mononuclear cell levels did not differ significantly between groups (Figure 4). In young rats, portal areas, hepatic cords, sinusoids, and Kupffer cell distribution showed normal histological structure (Figure 5a). Increased vacuolization

was detected in hepatocytes of the aged group and attributed to lipid accumulation (Figure 5b). While bile duct proliferation occurred in small numbers in the portal areas of the young group (Figure 5c), the aged group showed widespread proliferation and an increase in mononuclear cells in those areas (Figure 5d).

Compared with the young group (Figure 6a), the amount of collagen around the portal area and vena centralis was increased in the aged group (Figure 6b); prominent collagen strands were observed around the sinusoids (Figure 6c); and fibrotic bridging between the portal areas was detected (Figure 6d). PAS staining for glycogen indicated that the staining intensity in hepatocytes of the elderly group was low or absent because of vacuolization (data not shown).

Gene Expression Results

Changes in mRNA expression levels of the genes IL-6, mTOR, Cas-3, and NF-kB were examined in the liver tissue of young and old rats (Figure 7). IL-6 and NF-kB expression levels increased with age; however, no statistically significant differences were observed between the two groups. On the other hand, mTOR levels have been shown to increase significantly with age.

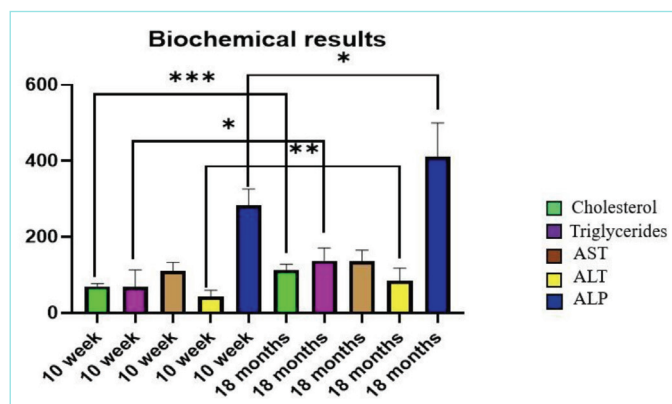


Figure 1. Comparison of biochemical enzymes in groups. *($p < 0.05$), **($p < 0.01$) and ***($p < 0.001$).

AST: Aspartate aminotransferase, ALT: Alanine transaminase, ALP: Alkaline phosphatase.

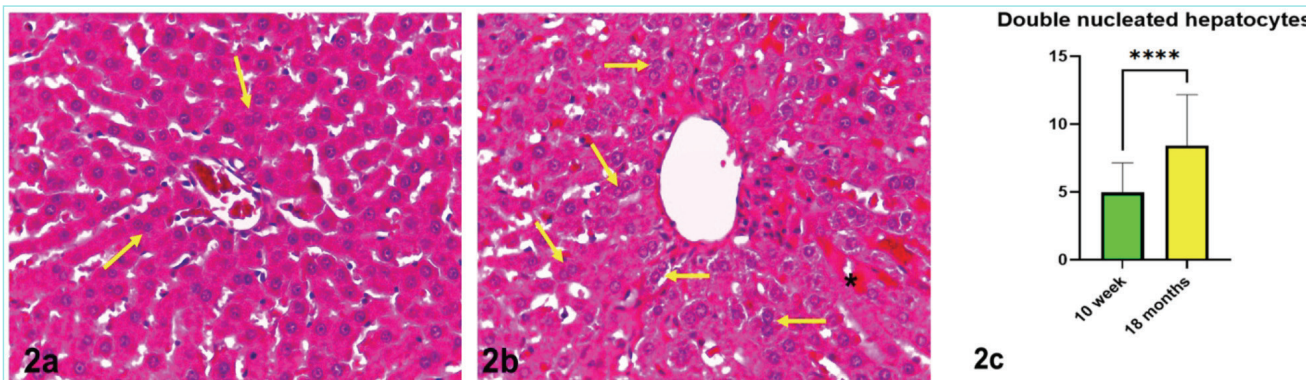


Figure 2. Binucleated hepatocytes (arrows) are present in both the young (2a) and aged (2b) groups; the statistical graph is shown in (2c, **** $p < 0.0001$), irregularity in hepatocyte cell cords and congestion in sinusoids (*) are observed in the aged group. Hematoxylin-eosin, x40.

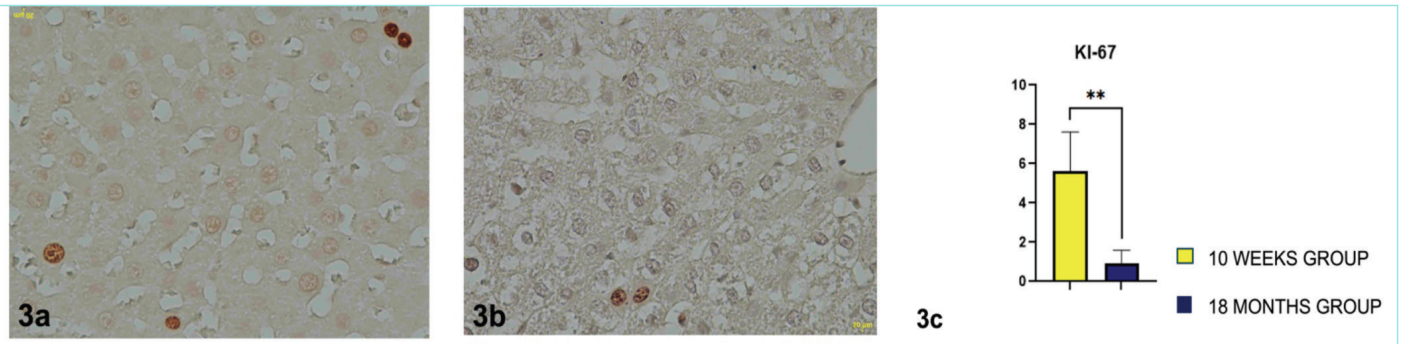


Figure 3. Ki-67 immunohistochemical staining in hepatocytes in young (3a) and aged groups (3b) and its statistical distribution (3c), x40. ******($p < 0.01$).

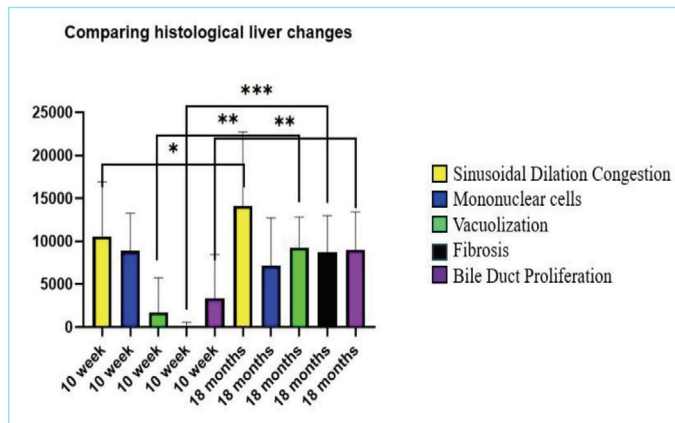


Figure 4. Quantitative histological scoring values in rats of different age groups. *****($p < 0.05$), ******($p < 0.01$) and *******($p < 0.001$).

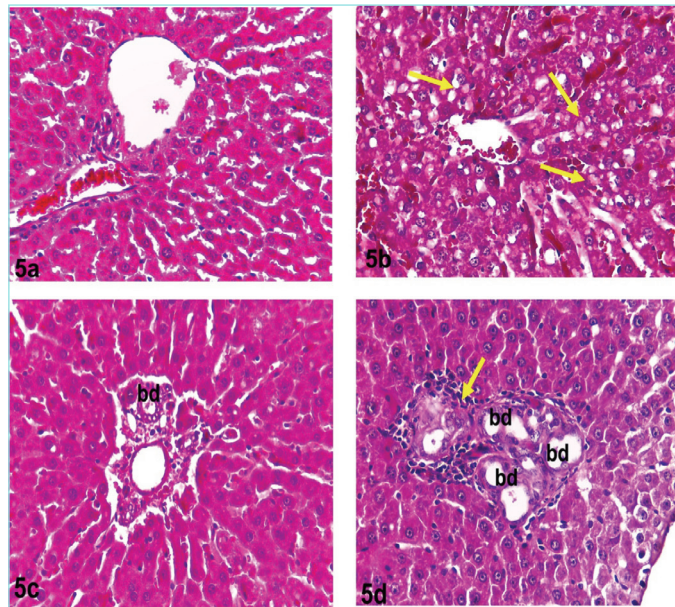


Figure 5. Light microscopic images of young and aged rat liver tissue. While normally structured hepatocytes, sinusoids, the portal area are observed in the livers of young rats (5a), widespread vacuolization (arrow) is observed in hepatocytes of the aged group (5b). Bile duct (bd) proliferation is markedly increased in the aged group compared with the young group. Mononuclear cells (arrow) (5c, 5d). Hematoxylin-eosin, x40.

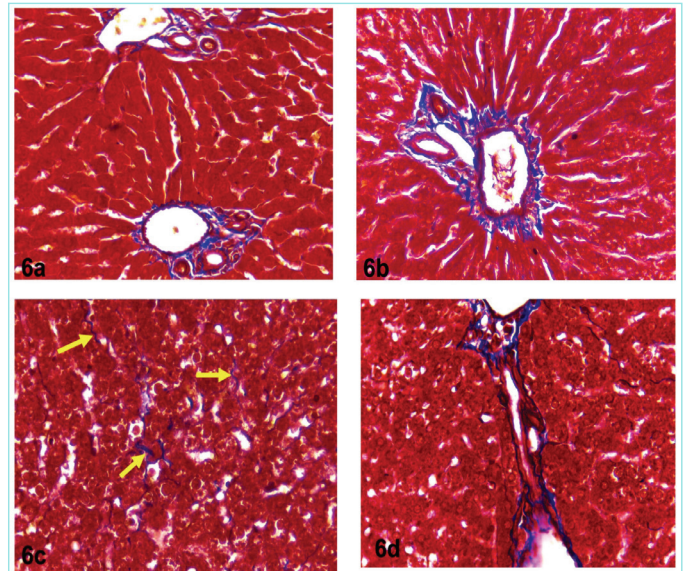


Figure 6. In contrast to the normal distribution of collagen fibers within the portal areas in the young group (6a), the aged group exhibits a significant increase in collagen in the portal areas (6b) and around the sinusoids (arrows) (6c), together with the formation of connective tissue bridges between the portal areas (6d). Masson trichrome stain, x40.

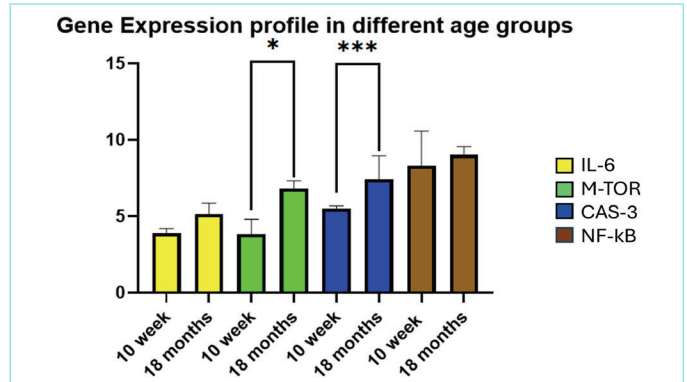


Figure 7. Gene expression levels in groups. *****($p < 0.05$), and *******($p < 0.001$).

IL-6: Interleukin-6, NF-kB: Nuclear factor kappa B, mTOR: Mammalian target of rapamycin, Cas-3: Caspase-3.

In the older group, mTOR levels were nearly twofold higher than in the 10-week group ($p < 0.05$). This result demonstrates the potential role of mTOR in regulating autophagy and aging processes. An age-related increase in Cas-3 expression was also observed. It was significantly increased in the 18-month group ($p < 0.001$). These results further emphasize the role of Cas-3 in the aging process and reflect an increase in apoptotic activity.

DISCUSSION

This study examined changes in histological features and in the expression of biochemical and molecular markers associated with aging in rat liver tissue. Aging generally leads to decreased liver size and weight, and to alterations in biochemical enzyme activity. Although subtle signs of cellular aging were observed in the liver tissues of young adult rats, these changes were offset by the liver's regenerative capacity. In aged rats, both senescence and decreased regenerative capacity result in a prolonged or absent regenerative process.^{14,15} Elevated AST and ALT levels have been reported in older adults in previous studies.^{16,17}

Although a decrease in liver weight was observed in the aged group compared with the young group in this study, the difference was not statistically significant. Biochemically, increases in ALP and ALT levels were significant, but not in AST levels. Significant increases in cholesterol and triglyceride levels were also observed in the aged group.

It is known that aging hepatocytes generally lose some of their regenerative capacity.⁶ Extracellular matrix components are altered, leading to fibrosis.¹⁸ This results in impaired blood flow and altered hepatocyte function. The distribution and function of nonparenchymal cell populations, such as liver Kupffer cells and stellate cells, change during the aging process.^{15,19} When Kupffer cells are insufficient to clear pathogens and debris, activated stellate cells cause fibrosis. This study identified fibrosis in the elderly group, with increased collagen fibers in the portal areas and around the sinusoids and central vein.

Another change that can occur in the liver with age is bile duct proliferation.²⁰ Increased bile duct proliferation in portal areas was assessed for its association with increased ALP.

Furthermore, aging causes increases in inflammatory molecules such as IL-6 and NF- κ B, and alterations in immune cell function, ultimately leading to increased susceptibility to infections and diseases.^{21,22} Although expression levels of IL-6 and NF- κ B were increased in the elderly group, these differences were not statistically significant. Light microscopic examination confirmed this finding; inflammatory cell populations were not widespread.

Polyplody increases in aged hepatocytes. This change appears to be a compensatory mechanism to cope with the decline in cell division capacity in aging tissues.²³ In our study, the number of binucleated hepatocytes was significantly higher in the aged group than in the younger group. Furthermore, a significantly greater number of hepatocyte nuclei stained positive for Ki-67 in the aged group. Increased hepatocyte proliferation and polyplody are adaptive mechanisms that help maintain liver function despite age-related decline.

Cas-3-controlled apoptosis in the liver is important for cellular homeostasis and prevents the proliferation of harmful cells that lead to liver disease. During aging, some degenerating hepatocytes undergo apoptosis.^{9,10,24} Studies have shown an increase in Cas-3 expression and

activity during aging. The increased Cas-3 gene expression in the liver of our elderly experimental group is consistent with this information.

Autophagy, on the other hand, is a cellular defense mechanism that removes and recycles damaged organelles and proteins, maintaining homeostasis and cellular function. Fibrosis, along with increased steatosis and inflammation, has been associated with impaired hepatic autophagy.²⁵ Therefore, autophagy is considered a strategy for restoring age-related hepatic changes and for highlighting the complex relationships between aging, dietary habits, and environmental factors in liver histology.⁸ Autophagy is active in young rats and underlies the high functional activity and cellular resilience of the liver.²⁶ Autophagic activity decreases with aging. This decrease is associated with the onset of mild cellular dysfunction, as the liver begins to show signs of accumulation of oxidative stress and of lipid peroxidation products.²⁷ The autophagic process is regulated by mTOR kinase.²⁸ The mTOR signaling pathway is a key genetic factor in liver aging and plays a crucial role in cellular growth and metabolism. Therefore, inhibition of mTOR potentially extends lifespan and significantly delays signs of pathological aging in rat livers. This inhibition leads to reduced fibrosis and improved cellular function.²⁹⁻³¹ This study found increased *mTOR* gene expression in liver tissue in the elderly group, in contrast to other studies. These results demonstrate that during aging, cells continue to attempt to slow the aging process and protect themselves.

Study Limitations

Disadvantages of the study included a small number of subjects in the groups, the inability to define fibrosis morphometrically and biochemically, and the inability to perform immunohistochemical staining of genetically expressed molecules in the tissue.

CONCLUSION

Liver aging is a complex process, and some events remain unexplained. Changes in liver structure and function among individuals of the same age, and between women and men, vary depending on factors such as living conditions, nutrition, and genetic background. The differences between the results obtained in our study - such as high mTOR levels, increased Ki-67 related to mitotic changes, low AST enzyme levels, no significant change in liver weight, and absence of inflammation - and those reported in other studies can be explained by individual differences. The mechanisms and molecules that contribute to the aging process require more detailed investigation. Delaying or preventing age-related functional disorders and chronic diseases will be the primary focus of the studies.

MAIN POINTS

- Aging caused significant increases in cholesterol, triglyceride, alanine transaminase, and alkaline phosphatase levels, indicating altered liver metabolism.
- The aged group showed vacuolization, sinusoidal congestion, bile duct proliferation, collagen accumulation, and more Ki-67-positive and binucleated hepatocytes, reflecting structural and regenerative changes.
- *mTOR* and *Cas-3* gene expressions were upregulated in aged livers, suggesting enhanced autophagic and apoptotic activity.

- Interleukin-6 and nuclear factor kappa B levels did not differ significantly between groups, indicating no prominent inflammatory response.
- Physiological aging leads to histological, apoptotic, and autophagic changes that impair liver function, with variations likely influenced by genetic and environmental factors.

ETHICS

Ethics Committee Approval: The protocols are based on animal experiments approved by the Near East University Experimental Animals and Research Centre Ethics Committee of Research and Application Center (approval number: 2024/175, date: 18.04.2024).

Informed Consent: There is no informed consent.

Footnotes

Authorship Contributions

Surgical and Medical Practices: Y.A.H., G.K., M.T., Concept: A.K., Design: Y.A.H., Data Collection and/or Processing: Y.A.H., G.K., M.T., Analysis and/or Interpretation: Y.A.H., G.T., G.Ö., O.E., T.F., A.K., Literature Search: Y.A.H., G.Ö., A.K., Writing: Y.A.H., G.Ö., A.K.

DISCLOSURES

Conflict of Interest: No conflict of interest was declared by the authors.

Financial Disclosure: The authors declared that this study received no financial support.

REFERENCES

- Regulski MJ. Cellular senescence: what, why, and how. *Wounds*. 2017; 29(6): 168-74.
- Li Q, Xiao N, Zhang H, Liang G, Lin Y, Qian Z, et al. Systemic aging and aging-related diseases. *FASEB J*. 2025; 39(5): e70430.
- Silva-García CG. Devo-aging: intersections between development and aging. *Geroscience*. 2023; 45(4): 2145-59.
- Bajpai A, Li R, Chen W. The cellular mechanobiology of aging: from biology to mechanics. *Ann N Y Acad Sci*. 2021; 1491(1): 3-24.
- Sanfeliu-Redondo D, Gibert-Ramos A, Gracia-Sancho J. Cell senescence in liver diseases: pathological mechanism and theranostic opportunity. *Nat Rev Gastroenterol Hepatol*. 2024; 21(7): 477-92.
- Wang W, Xu K, Shang M, Li X, Tong X, Liu Z, et al. The biological mechanism and emerging therapeutic interventions of liver aging. *Int J Biol Sci*. 2024; 20(1): 280-95.
- Chen X, Lu T, Zheng Y, Lin Z, Liu C, Yuan D, et al. miR-155-5p promotes hepatic steatosis via PICALM-mediated autophagy in aging hepatocytes. *Arch Gerontol Geriatr*. 2024; 120: 105327.
- Xu F, Tautenhahn HM, Dirsch O, Dahmen U. Modulation of autophagy: a novel "Rejuvenation" strategy for the aging liver. *Oxid Med Cell Longev*. 2021; 2021: 6611126.
- Zhong HH, Hu SJ, Yu B, Jiang SS, Zhang J, Luo D, et al. Apoptosis in the aging liver. *Oncotarget*. 2017; 8(60): 102640-52.
- Hu SJ, Jiang SS, Zhang J, Luo D, Yu B, Yang LY, et al. Effects of apoptosis on liver aging. *World J Clin Cases*. 2019; 7(6): 691-704.
- Li X, Li C, Zhang W, Wang Y, Qian P, Huang H. Inflammation and aging: signaling pathways and intervention therapies. *Signal Transduct Target Ther*. 2023; 8(1): 239.
- Mohammed S, Thadathil N, Selvarani R, Nicklas EH, Wang D, Miller BF, et al. Necroptosis contributes to chronic inflammation and fibrosis in aging liver. *Aging Cell*. 2021; 20(12): e13512.
- de Lima EC, de Moura CFG, Silva MJD, Vilegas W, Santamarina AB, Pisani LP, et al. Therapeutic properties of *Mimosa caesalpinhiifolia* in rat liver intoxicated with cadmium. *Environ Sci Pollut Res Int*. 2020; 27(10): 10981-9.
- Mittal K, Kashyap K, Anupam, Dhar M. A short review of radiological changes of liver with aging. *Biomed J Sic Tech Res*. 2023; 50(3): 41608-10.
- Delire B, Lebrun V, Selvais C, Henriot P, Bertrand A, Horsmans Y, et al. Aging enhances liver fibrotic response in mice through hampering extracellular matrix remodeling. *Aging (Albany NY)*. 2016; 9(1): 98-113.
- Saleh DO, Mansour DF, Hashad IM, Bakeer RM. Effects of sulforaphane on D-galactose-induced liver aging in rats: role of keap-1/nrf-2 pathway. *Eur J Pharmacol*. 2019; 855: 40-9.
- Rahimi Naiini M, Shahouzehi B, Khaksari M, Azizi S, Naghibi N, Nazari-Robati M. Ellagic acid reduces hepatic lipid contents through regulation of SIRT1 and AMPK in old rats. *Arch Physiol Biochem*. 2024; 130(6): 686-93.
- Hunt NJ, Kang SWS, Lockwood GP, Le Couteur DG, Cogger VC. Hallmarks of aging in the liver. *Comput Struct Biotechnol J*. 2019; 17: 1151-61.
- Zhong L, Zhao J, Huang L, Liu Y, Pang X, Zhan K, et al. Runx2 activates hepatic stellate cells to promote liver fibrosis via transcriptionally regulating Itgav expression. *Clin Transl Med*. 2023; 13(7): e1316.
- Kundu D, Kennedy L, Meadows V, Baiocchi L, Alpini G, Francis H. The dynamic interplay between mast cells, aging/cellular senescence, and liver disease. *Gene Expr*. 2020; 20(2): 77-88.
- Biazi GR, Uemura IGF, Miksza DR, Ferraz LS, Diaz BF, Bertolini GL, et al. Interleukin 6 acutely increases gluconeogenesis and decreases the suppressive effect of insulin on cAMP-stimulated glycogenolysis in rat liver. *Cell Biochem Funct*. 2023; 41(5): 609-18.
- Li J, Xian L, Zheng R, Wang Y, Wan X, Liu Y. Canthaxanthin shows anti-liver aging and anti-liver fibrosis effects by down-regulating inflammation and oxidative stress in vivo and in vitro. *Int Immunopharmacol*. 2022; 110: 108942.
- Zhao Y, Yang Y, Li Q, Li J. Understanding the unique microenvironment in the aging liver. *Front Med (Lausanne)*. 2022; 9: 842024.
- Ouyang Z, Yang B, Yi J, Zhu S, Lu S, Liu Y, et al. Exposure to Fluoride induces apoptosis in liver of ducks by regulating Cyt-C/Caspase 3/9 signaling pathway. *Ecotoxicol Environ Saf*. 2021; 224: 112662.
- Zhao C, Wu B, Li J, Jiang Q, Looor JJ, Liu M, et al. AdipoRon alleviates fatty acid-induced lipid accumulation and mitochondrial dysfunction in bovine hepatocytes by promoting autophagy. *J Dairy Sci*. 2023; 106(8): 5763-74.
- Wang H, Li X, Zhang Q, Fu C, Jiang W, Xue J, et al. Autophagy in disease onset and progression. *Aging Dis*. 2024; 15(4): 1646-71.
- He QJ, Li YF, Zhao LT, Lin CT, Yu CY, Wang D. Recent advances in age-related metabolic dysfunction-associated steatotic liver disease. *World J Gastroenterol*. 2024; 30(7): 652-62.
- Johnson SC. Nutrient sensing, signaling and ageing: the role of IGF-1 and mTOR in ageing and age-related disease. *Subcell Biochem*. 2018; 90: 49-97.
- Johnson SC, Rabinovitch PS, Kaeberlein M. mTOR is a key modulator of ageing and age-related disease. *Nature*. 2013; 493(7432): 338-45.
- Hassani B, Goshtasbi G, Nooraddini S, Firouzabadi N. Pharmacological approaches to decelerate aging: a promising path. *Oxid Med Cell Longev*. 2022; 2022: 4201533.
- Maldonado-Rengel R, Sócola-Barsallo Z, Vásquez B. Alterations of liver morphology in senescent rats. *Int J Mol Sci*. 2024; 25(18): 9846.